

## Research Article

# Comparison of contact surface areas of metatarsal diaphyseal osteotomies for correction of hallux valgus: Experimental study

A. Meriç Ünal<sup>1,2</sup> , Aydın Budeyri<sup>3</sup> , Bahattin Baykal<sup>4</sup> <sup>1</sup>Department of Sports Medicine, Süleyman Demirel University, School of Medicine, Isparta, Turkey<sup>2</sup>Clinic of Orthopaedics and Traumatology, Isparta City Hospital, Isparta, Turkey<sup>3</sup>Department of Orthopaedics and Traumatology, SANKO University, School of Medicine, Gaziantep, Turkey<sup>4</sup>Department of Radiology, Süleyman Demirel University, School of Medicine, Isparta, Turkey

## ARTICLE INFO ABSTRACT

## Article history:

Submitted 17 October 2017

Received in revised form

10 September 2018

Last revision received

7 April 2020

Accepted 8 May 2020

## Keywords:

Hallux valgus

Metatarsal osteotomy

Metatarsal diaphysis osteotomy

Metatarsal shaft osteotomy

Contact surface area

## ORCID iDs of the authors:

A.M.Ü. 0000-0001-9576-5994;

A.B. 0000-0003-1894-5435;

B.B. 0000-0001-8439-1616.

**Objective:** This study aimed to determine, pre-correction, the potential change in the osteotomy-site bony contact surface area that would occur during standard metatarsal diaphyseal procedures with the Baran-Unal modification of Mau osteotomy and then to compare it, post-correction, with the actual osteotomy-site bony contact surface area changes for a standard degree of deformity correction.

**Methods:** A total of 30 standard, same sized, biomechanically equivalent, left first metatarsal sawbones were included in this experimental study. They were divided equally into five groups for each of the planned osteotomy techniques: Myerson's modification of Ludloff, Mau, scarf, Offset V, and Baran-Unal modification of Mau osteotomy. The normal osteotomy for each sample was considered as the control, while the corrective osteotomy was the test. Computerized tomography scans and three-dimensional (3D) reconstruction imaging were performed for objective and accurate measurements. The techniques of the osteotomy and post-corrective osteotomy bony contact surface areas were investigated by the two independent research assistants.

**Results:** There was a statistically significant difference between the contact surface area changes of all pre- and post-corrective osteotomy groups ( $P < 0.05$ ). When the pre- and post-correction contact surface areas of any one group were compared with the other groups, the differences were or were not statistically significant. Mean differences between pre-correction and post-correction areas for Ludloff, Mau, scarf, Offset V, and Baran-Unal osteotomies were 180.7, 122.3, 226.2, 191.9, and 68.9 mm<sup>2</sup>, and the percentages of area loss were 22.9%, 15.5%, 28.6%, 24.3%, and 8.7%, respectively. The most bony contact area was found in the scarf osteotomy group (mean pre-correction area: 490.5 mm<sup>2</sup> and mean post-correction area: 264.3 mm<sup>2</sup>), but the Baran-Unal modification group has significantly the highest post-correction bony contact area among the all other groups (mean pre-correction area: 413.3 mm<sup>2</sup> and mean post-correction area: 344.4 mm<sup>2</sup>).

**Conclusion:** Metatarsal diaphyseal osteotomies for hallux valgus deformity have the potential not only for deformity correction, but also for contact surface area preservation. This study reaffirms the considerable potential of this new Baran-Unal modification to confer outstanding contact surface area values, even with the operative correction of hallux valgus deformity.

Various techniques for the surgical treatment of the hallux valgus deformity have been reported (1, 2). Despite the variety of available techniques, the gold standard surgical procedure has yet to be devised (3). As validated by the latest research literature, osteotomies of the first metatarsal bone are the treatment of choice for moderate and severe cases of hallux valgus (4). In addition to proximal metatarsal osteotomies, diaphyseal osteotomies may have satisfactory outcomes and may also offer more potential to correct angular deformity. Metatarsal diaphyse-

al osteotomies make it possible to minimize the decrease in the post-osteotomy bony contact surface area, resulting in only a minor decrease in the metatarsal length (5). Many metatarsal diaphyseal osteotomies have been described. Some of the more common osteotomy types are Ludloff (5), Mau (6), scarf (7), and Offset V (modified chevron) (8). The purpose of modifications is to increase the osteotomy-site bony contact surface area (OSBCSA), preserve original metatarsal length, and improve osteotomy stability and union rates, as metatarsal shorten-

## Corresponding Author:

A. Meriç Ünal

abdmunal@yahoo.com



Content of this journal is licensed under a Creative Commons Attribution-NonCommercial 4.0 International License.

**Cite this article as:** Ünal AM, Budeyri A, Baykal B. Comparison of contact surface areas of metatarsal diaphyseal osteotomies for correction of hallux valgus: Experimental study. *Acta Orthop Traumatol Turc* 2020; 54(4): 430-7.

ing and dorsal angulation frequently complicate metatarsal osteotomies (9-13).

Diaphyseal osteotomies are gaining popularity for the surgical correction of hallux valgus because they offer several advantages such as versatility, inherent stability, minimal first metatarsal shortening, good intermetatarsal reduction, and ease of rigid internal fixation (14). Strong and stable internal fixation allows for earlier functional recovery and primary bone healing. Diaphyseal osteotomies can provide predictable and rewarding results for both the patient and the surgeon.

Despite the popularity of metatarsal osteotomies, including diaphyseal procedures, and the increasing body of available clinical and experimental evidence, there are no studies that we know of that explore the relationship between the OSBCSA and the correction angle among the different techniques. We devised and published a new modification of Mau osteotomy, named Baran–Unal modification, in order to obtain better osteotomy reduction and stability by increasing the OSBCSA (14). Our modification incorporates the following features into the original Mau technique: (i) plane of the osteotomy is parallel to the plantar surface, (ii) proximal beginning of the osteotomy is L-shaped with its angle facing the plantar surface, and (iii) proximalization of the osteotomy center of rotation (14).

This study aimed to determine, pre-correction, the potential change in the OSBCSA that would occur during each of the Ludloff, scarf, Mau, Offset V, and Baran–Unal procedures and then compare it, post-correction, with the actual OSBCSA changes, for a 10° of angulation for deformity correction, and investigate the presence of overcorrectional deformity.

## Materials and Methods

### Samples, groups, and procedures

A total of 30 standard, same sized, biomechanically equivalent, left first metatarsal sawbones (Sawbones, Malmö, Sweden) were included in this experimental study. They were divided equally into five groups for each of the planned oste-

otomy techniques: Myerson’s modification of Ludloff (group L), Mau (group M), scarf (group S), Offset V (group OV), and Baran–Unal modification (group BU) (Figure 1). In the Baran–Unal technique, a diaphyseal osteotomy is performed from the distal dorsal side of the first metatarsal through the proximal plantar side and the osteotomy ends with a notch that has a 70° angle with the main osteotomy (Figure 1: Fourth osteotomy) (14). All corrections except scarf osteotomy were performed with rotation. Corrections for scarf osteotomy were performed with sliding the fragments on each other. The aforementioned metatarsal osteotomies were performed on the six samples from each group, which were followed by standard 10° angulation with a standard grooved wooden guide (Figure 2). The osteotomy bony contact area before correction for each sample was considered as the control, while the osteotomy after correction was the test.

### Test protocol

Tested specimens were fixed in a rigid molding device. This was the utilized setting to mold and osteotomize all the controls and tests for all the five techniques under study. A novel wooden guide (Figure 2) was designed for the osteotomies so that all the procedures would be accurate, standardized, and equivalent. The

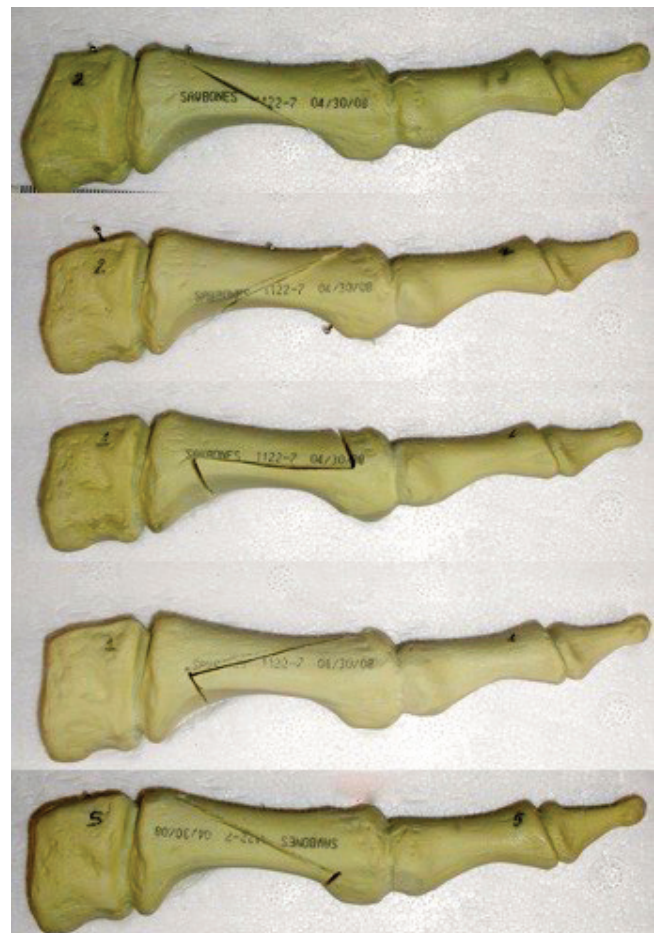

Figure 1. Performed standard Ludloff, Mau, scarf, Offset V, and Baran–Unal osteotomies (in order from up to down)

### HIGHLIGHTS


- Potential changes in the osteotomy-site bony contact surface areas (OSBCSAs) in case of various osteotomy techniques are determined and compared with the actual OSBCSA changes post-correction.
- Ludloff, scarf, Mau, Offset V, and Baran–Unal procedures were considered.
- Computerized tomography scans and three-dimensional reconstruction imaging were employed.
- Baran–Unal modification of Mau osteotomy shows great potential in terms of achieved OSBCSA, even in the surgical correction of hallux valgus deformity.

same guide was used for all osteotomy procedures. The osteotomies and correction standards were controlled by two independent research assistants who were blind to the study hypothesis.

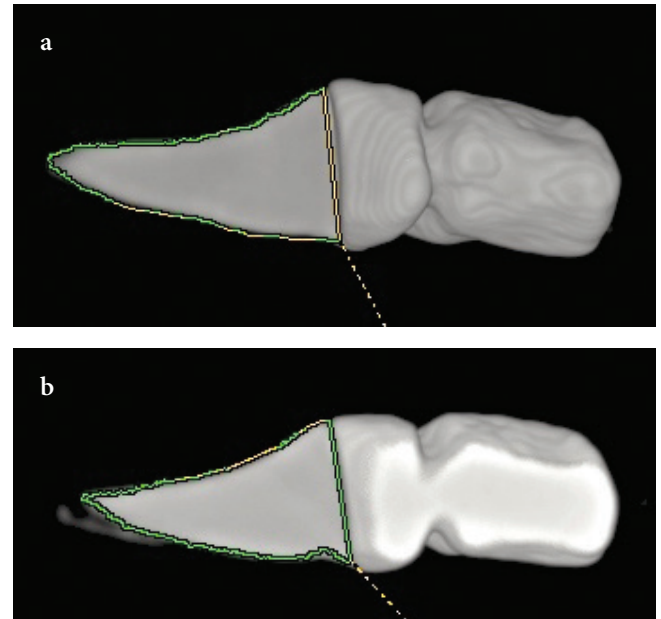
**Osteotomies and corrections**

Among the four osteotomy groups (except scarf osteotomy), complementary correction maneuvers were performed by the rotation of the fragments (Figure 1). For the scarf osteotomy group, correction was made by translating the proximal and distal surfaces on each other. After each osteotomy, contact surfaces of the proximal fragments of the samples were marked with a marker pen. There was no need for fixation of

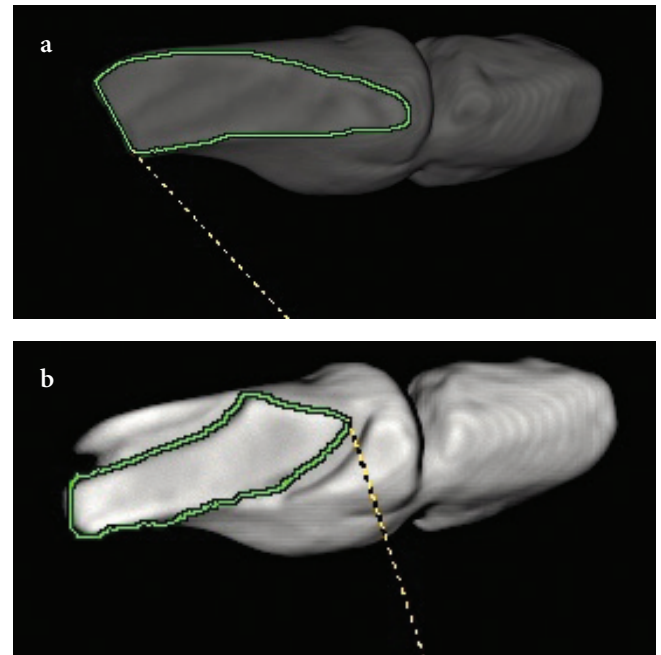
the fragments because we needed the fragments separately for the computerized tomography (CT) scan. The standardization and the uniformity controls, as well as confirmations of the osteotomies, correction maneuvers, reductions, fixations, and measurements, were all performed by two independent observers who were blind to the study hypothesis. All the aforementioned steps were rated by the two independent research assistants stepwise from 0 to 10, with 0 being “not standard”



**Figure 2.** The wooden guide to provide standard 10° angulation and translation of the osteotomies. Notch-X: Notch for medial cuneiform. Notch-Y: Notch for distal metatarsal and sesamoids. Notch-Z: Notch for distal metatarsal and sesamoids after correction. Line A (Red line): Standard longitudinal position line of the metatarsal bone before correction. Line B (Blue line): Standard longitudinal position line after 10° correction. Ludloff, Mau, Offset V, and Baran-Unal osteotomies were moved from Line A to Line B with metatarsal osteotomy rotation. Same route was achieved for scarf osteotomy with translation of osteotomy fragments on each other



**Figure 3. a, b.** Pre- and post-correction osteotomy-site contact surface area 3D CT scan measurement of Baran-Unal osteotomy



**Figure 4. a, b.** Pre- and post-correction osteotomy-site contact surface area 3D CT scan measurement of Ludloff osteotomy

and 10 being “completely standard.” Subsequently, the mean of overall research quality agreement correlations was calculated. The mean of inter-rater and intra-rater overall research quality correlations were  $r=0.750$  and  $r=0.823$ , respectively.

**Measurements**

The borderlines of the surfaces were then notched for 3 mm circumferentially to create detectable margins on the CT scan

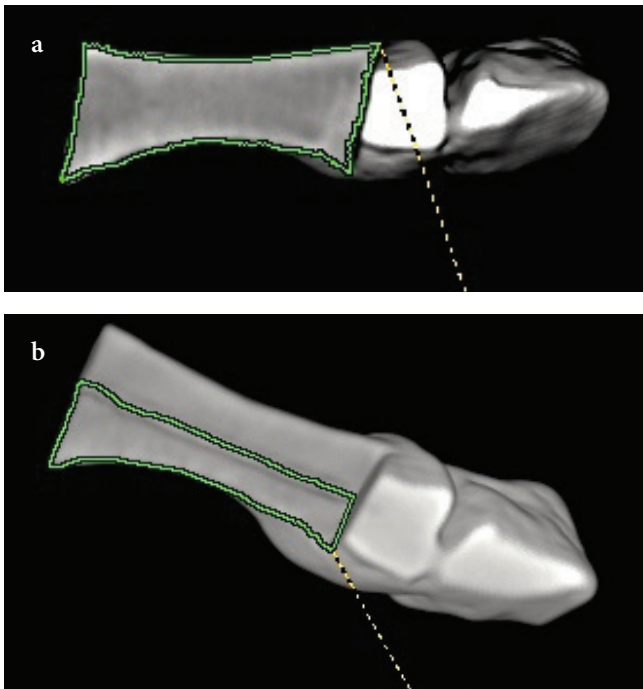


Figure 5. a, b. Pre- and post-correction osteotomy-site contact surface area 3D CT scan measurement of scarf osteotomy

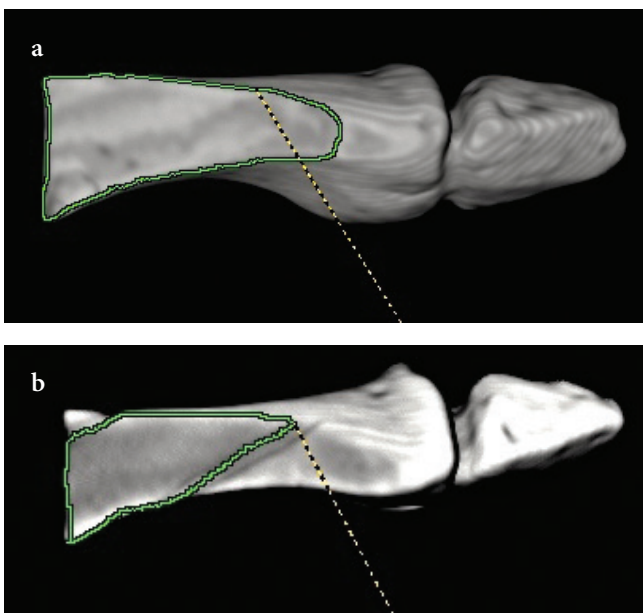


Figure 6. a, b. Pre- and post-correction osteotomy-site contact surface area 3D CT scan measurement of Offset V osteotomy

(Brivo CT325, GE Healthcare, Chicago, IL, USA) (Figures 3–7). Following the osteotomy and corrections, the control and test samples were placed on a custom-designed sponge holder (Figure 8), and CT scans of 1-mm slice thickness were

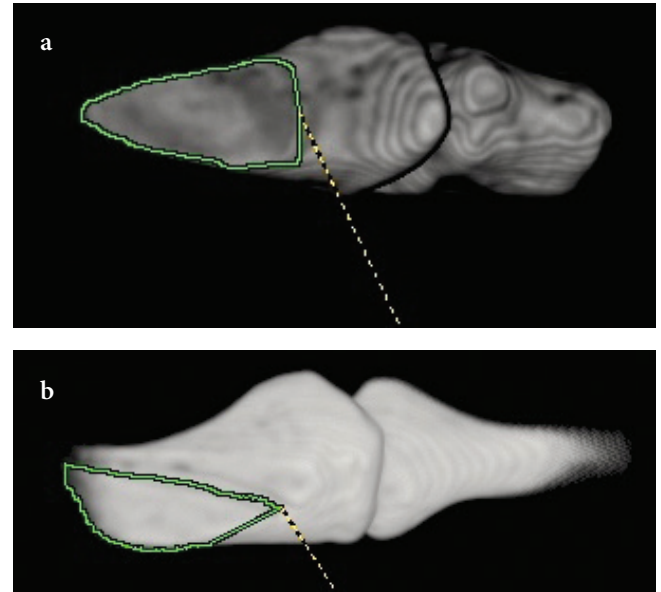


Figure 7. a, b. Pre- and post-correction osteotomy-site contact surface area 3D CT scan measurement of Mau osteotomy




Figure 8. The sponge holder to fix the proximal fragments of the osteotomies stable during CT scan

taken to obtain objective and accurate measurements of the pre-correction and post-correction osteotomy bony contact surface areas. The pre- and post-correction proximal bony contact surface areas were scanned, and contacting proximal–distal surface areas were digitally measured through the default official computer software supplied with the CT.

**Statistical analysis**

Three statistical analyses were performed between the pre-correction OSBCSA (surface area of the osteotomy after osteotomy before correction) among the groups, the post-correction OSBCSA among the groups, and the pre- and post-correction OSBCSA among the groups, respectively. Since the data for the five different osteotomy groups were heterogenic and nonparametric, Mann-Whitney U and Wilcoxon tests were performed to compare their contact surface area changes. The Kruskal–Wallis test was performed to compare the pre- and

post-corrective osteotomy surface area changes, as well as to compare the nonparametric data group medians that included independent, multiple variables. Cohen’s kappa correlation coefficients were calculated for the ratings and agreements. Statistical analyses were performed via the Statistical Package for Social Sciences version 22.0 for Windows (IBM SPSS Corp.; Armonk, NY, USA). A two-sided p value less than 0.05 was defined as statistically significant.

**Results**

The mean osteotomy-site pre-correction bony contact surface areas (mOSPreCBCSAs), mean osteotomy-site post-correction bony contact surface areas (mOSPostCBCSAs), correctional contact surface area differences (CCSADs), and correctional contact surface area decrease rates (CCSADRs) are shown in Table 1.

**Table 1.** The mean osteotomy-site pre- and post-correction contact surface area measurements

	mOSPreCCSA <sup>a</sup> (mm <sup>2</sup> )	mOSPostCCSA <sup>b</sup> (mm <sup>2</sup> )	CCSAD <sup>c</sup> (mm <sup>2</sup> )	CCSADR <sup>d</sup> (%)
Ludloff	376	195.3	180.7	22.9
Mau	300.5	178.2	122.3	15.5
Scarf	490.5	264.3	226.2	28.6
Offset V	468.9	277	191.9	24.3
Baran–Unal	413.3	344.4	68.9	8.7

<sup>a</sup>mOSPreCCSA: Mean osteotomy-site post-correction contact surface area  
<sup>b</sup>mOSPostCCSA: Mean osteotomy-site post-correction contact surface area  
<sup>c</sup>CCSAD: Correctional contact surface area difference  
<sup>d</sup>CCSADR: Correctional contact surface area decrease rate

**Table 2.** Comparison of p values of pre-correction bony surface contact areas of osteotomies.

	Baran–Unal	Mau	Scarf	Offset V	Ludloff
Baran–Unal	–	0.004	0.01	0.055	0.109
Mau	0.004	–	0.004	0.004	0.004
Scarf	0.01	0.004	–	0.004	0.004
Offset V	0.055	0.004	0.004	–	0.037
Ludloff	0.109	0.004	0.004	0.037	–

**Table 3.** Comparison of p values of post-correction bony surface contact areas of osteotomies

	Baran–Unal	Mau	Scarf	Offset V	Ludloff
Baran–Unal	–	0.004	0.01	0.025	0.004
Mau	0.004	–	0.004	0.004	0.15
Scarf	0.01	0.004	–	0.631	0.006
Offset V	0.025	0.004	0.631	–	0.06
Ludloff	0.004	0.15	0.006	0.06	–

When the pre- and post-correction contact surface areas of any one group were compared with the other groups, the differences were or were not statistically significant. The p values among all groups for pre-correction and post-correction surface contact areas were listed in Tables 2 and 3, respectively.

## Discussion

The initial stability of various metatarsal diaphyseal osteotomies has been well studied, as is evident from the hallux valgus surgical biomechanics literature, but studies focusing on factors that confer stability specifically at the osteotomy site are few. Easley et al. showed that initial correction stability and postoperative functional recovery were highly dependent on osteotomy designs (15). Robinson et al. reported that proper healing and functional outcomes may be impaired when osteotomy reduction displacement or correction instability occurs (3). Osteosynthesis techniques have a fundamental role in providing reliable stability to hallux valgus deformity correction and fixation, but we believe that the mOSPostCBCSA is also a key factor to guarantee long-term stability, union, and healing. Therefore, we designed this study to introduce our new mid-shaft osteotomy technique, the Baran–Unal modification, which focuses on the alteration of the mOSPostCBCSA and compares the pre- and post-correction contact surface area alterations with other popular mid-shaft metatarsal osteotomies such as Ludloff, Offset V, scarf, and Mau. As demonstrated by Vienne et al. and Favre et al., osteotomy designs are significant determinants of bone healing response through their effects of osteotomy geometry and related stress patterns at the osteotomy site (16, 17).

We set out to investigate whether there were any statistically significant differences between five osteotomy techniques, Ludloff, scarf, Mau, Offset V, and Baran–Unal modification, in the potential alteration of their mOSPreCBCSA, and, if there were such differences, to quantitatively determine, for a 10° correction of deformity, the actual change in the mOSPostCBCSA specific for each technique. In this study, the mOSPreCBCSA was the highest for the scarf group (group S) and then, in descending order, Offset V (group OV), Baran–Unal modification (group BU), Ludloff (group L), and Mau (group M). The post-correction OSBCSA was the highest in group BU and then, in descending order, groups OV, S, L, and M. CCSADs were the highest in group S and then, in descending order, groups OV, L, M, and BU. CCSADRs were the highest in group S and then, in descending order, groups OV, L, M, and BU.

We observed that mOSPreCBCSAs for all of the five techniques were acceptable, but the contact surface area decreased to a different extent for each technique after distal bone fragment abduction maneuvers to institute a deformity correction of 10°. This decrease in the contact surface area is

important. However, we note that the type of diaphyseal osteotomy selected to correct a severe hallux valgus deformity is often based on the deformity and not the potential post-correction proximal and distal OSBCSA alterations. This is why we have attempted to modify and improve an established diaphyseal osteotomy technique by prioritizing the mOS-PostCBCSA outcome. Our hypothesis was that the design of a metatarsal diaphyseal osteotomy technique should not be based on the deformity alone, but it should also consider the potential mOSPostCBCSA changes, to maximize post-correction reduction quality, stability, healing, and functional outcomes in the operative treatment of severe hallux valgus. For similar reasons, potential post-correction contact surface area alterations should be considered for proximal and distal metatarsal osteotomies as well.

Our findings indicate that the mOSPostCBCSA can be substantially preserved when diaphyseal osteotomies are designed with a focus to achieve this objective. The results of our study show that the Mau osteotomy technique ranked the lowest for both the mOSPreCBCSA and the mOSPostCBCSA. However, with our modification of this technique, group BU achieved the highest mOSPostCBCSA of all the five procedures. The Baran–Unal modification promises superior outcomes with its lower CCSAD and CCSADR (Table 1).

Scarf osteotomy had the highest pre-correction contact surface area as well as the highest CCSAD and CCSADR because of its particular design and geometry. Vienne et al. found that the stability achieved through a reversed-L osteotomy was similar to a chevron osteotomy, and the reason was that both had a comparable and substantial interfragmentary bony contact surface (17). Helmy et al. explained the enhanced stability and benefit of a reversed-L osteotomy in hallux valgus treatment in terms of its superior capacity to preserve the contact surface area (18). We compared the mOSPreCBCSA and the mOSPostCBCSA for all five techniques to ascertain, qualitatively, the presence of a CCSADR (Table 1).

Other studies have explored the relationship between corrective osteotomy geometrics, including contact surface area considerations and stability outcomes. Acevedo et al. and Nyska et al. were among the first to investigate along these lines (19, 20). In our study, group S was significantly superior to groups L and M, but inferior to groups OV and BU with respect to the mOSPostCBCSA. Vienne et al. had noted the significantly compromised stability of scarf osteotomy (17). Popoff et al. reported on the fractures of the proximal dorsal bridge in an *in vitro* study, where all the metatarsal bones received a scarf osteotomy (21). Coetzee et al. found a 10% complication rate of scarf osteotomies (10). The Ludloff osteotomy group L was significantly superior to group M, but inferior to groups S and OV with respect to the mOSPostCBCSA (Table 1). Acevedo et al., in a sawbone and cadaver study

on Ludloff, scarf, proximal chevron, proximal crescentic, and Mau osteotomies, reported a similar relationship of biomechanical stability between proximal chevron and Ludloff osteotomies (19). They demonstrated that proximal chevron osteotomy was biomechanically more stable than crescentic and scarf osteotomies, but much less than a Ludloff osteotomy. Trnka et al. noted that Ludloff and scarf osteotomies have better stability characteristics than proximal crescentic and proximal chevron osteotomies (22). McCluskey et al. showed that for proximal crescentic osteotomies, screw fixations produced better fixation stabilities than K-wires (23). Shaw et al. discerned the higher stability of Offset V (proximal chevron) over scarf, Mau, and Ludloff osteotomies (24). Unal et al. investigated the biomechanical properties of these techniques and how they were linked to fixation-type stability alterations (14). They demonstrated that the new mid-shaft osteotomy modification, the Baran–Unal modification, had superior biomechanical screw fixation stability than Offset V, Ludloff, scarf, and Mau osteotomies. The new modification achieved this by bringing the osteotomy-site correction center of rotation more proximally and creating a reliable bony stock for a more stable screw fixation.

There were a few study limitations, including the use of synthetic bones. Even though the sample synthetic bones were biomechanically equivalent, they did not have a medullary channel, so some complications of the osteotomies, such as channel formation, could not be evaluated. Longitudinal loading test could not be performed on the synthetic bones as they lacked proximal and distal joint structures. Hence, the stability of the osteotomies, in particular the contribution of notched osteotomies, could not be assessed. Additionally, we were unable to find and use hallux valgus deformity simulated synthetic bones. Finally, because of the small number of samples, this study may have low statistical power. We used the statistical means of the measurements to provide additional support to our analysis and hypothesis.

In conclusion, diaphyseal osteotomies for hallux valgus deformity correction have the potential to substantially preserve the mOSPostCBCSA, when designed not only for deformity correction, but also for contact surface area preservation. This study shows that when Mau osteotomy, which yielded the lowest mOSPreCBCSA and mOSPostCBCSA, is modified with a focus to preserve the post-correction mOSPostCBCSA, via the Baran–Unal modification, it leads to the highest post-correction bony contact surface area, and the lowest CCSADR, when compared to several popular metatarsal mid-shaft osteotomies. The effect of optimal preservation of post-correction contact surface area on osteotomy reduction quality, biomechanical stability, and functional outcomes is a novel direction for future research, especially through randomized controlled trials. We introduced our novel Baran–Unal modification mid-shaft metatarsal oste-

otomy in a previously published study (14). This study reaffirms, under different settings, the considerable potential of this new modification to confer outstanding contact surface area values, even with the surgical correction of hallux valgus deformity.

**Ethics Committee Approval:** N/A.

**Informed Consent:** N/A.

**Author Contributions:** Concept - A.M.Ü., A.B., B.B.; Design - A.M.Ü., A.B., B.B.; Supervision - A.M.Ü., A.B., B.B.; Materials - A.M.Ü., A.B., B.B.; Data Collection and/or Processing - A.M.Ü., A.B., B.B.; Analysis and/or Interpretation - A.M.Ü., A.B., B.B.; Literature Search - A.B., B.B.; Writing Manuscript - A.M.Ü., A.B.; Critical Review - A.M.Ü., A.B., B.B.

**Conflict of Interest:** The authors have no conflicts of interest to declare.

**Financial Disclosure:** The authors declared that this study has received no financial support.

## References

1. Johnson AE, Georgopoulos G, Erickson MA, Eilert R. Treatment of adolescent hallux valgus with the first metatarsal double osteotomy: The Denver experience. *J Pediatr Orthop* 2004; 24: 358-62. [\[Crossref\]](#)
2. Peterson HA, Newman SR. Adolescent bunion deformity treated with double osteotomy and longitudinal pin fixation of the first ray. *J Pediatr Orthop* 1993; 13: 80-4. [\[Crossref\]](#)
3. Robinson AH, Limbers JP. Modern concepts in the treatment of hallux valgus. *J Bone Joint Surg Br* 2005; 87: 1038-45. [\[Crossref\]](#)
4. Rockett MS, Goss LR. Midshaft first-ray osteotomies for hallux valgus. *Clin Podiatr Med Surg* 2005; 22: 169-95. [\[Crossref\]](#)
5. Ludloff K. Die beseitigung des hallux valgus durch die schräge planta-dorsale osteotomie des metatarsus. *Langenbecks Arch Klin Chir Ver Dtsch Z Chir* 1918; 110: 364-87.
6. Mau C, Lauber H. Die operative Behandlung des hallux Valgus. *Deutsche Zeit Orthop* 1926; 197: 361-77. [\[Crossref\]](#)
7. Coetzee JC, Rippstein P. Surgical strategies: scarf osteotomy for hallux valgus. *Foot Ankle Int* 2007; 28: 529-35. [\[Crossref\]](#)
8. Vogler HW. The “off-set V” osteotomy in hallux valgus reduction. In: *Six schools of surgical thought (syllabus)*. Cleveland: Ohio College of Podiatric Medicine, 1985.
9. Bae SY, Schon LC. Surgical strategies: Ludloff first metatarsal osteotomy. *Foot Ankle Int* 2007; 28: 137-44. [\[Crossref\]](#)
10. Coetzee JC. Scarf osteotomy for hallux valgus repair: the dark side. *Foot Ankle Int* 2003; 24: 29-33. [\[Crossref\]](#)
11. Sammarco VJ. Surgical strategies: Mau osteotomy for correction of moderate and severe hallux valgus deformity. *Foot Ankle Int* 2007; 28: 857-64. [\[Crossref\]](#)
12. Sanhudo JA. Correction of moderate to severe hallux valgus deformity by a modified chevron shaft osteotomy. *Foot Ankle Int* 2006; 27: 581-5. [\[Crossref\]](#)
13. Sanhudo JA. Extending the indications for distal chevron osteotomy. *Foot Ankle Int* 2000; 21: 522-3. [\[Crossref\]](#)

14. Unal AM, Baran O, Uzun B, Turan AC. Comparison of screw-fixation stabilities of first metatarsal shaft osteotomies: A biomechanical study. *Acta Orthop Traumatol Turc* 2010; 44: 70-5. [\[Crossref\]](#)
15. Easley ME, Trnka HJ. Current concepts review: hallux valgus part 1: Pathomechanics, clinical assessment, and nonoperative management. *Foot Ankle Int* 2007; 28: 654-59. [\[Crossref\]](#)
16. Favre P, Farine M, Snedeker JG, Maquieira GJ, Espinosa N. Biomechanical consequences of first metatarsal osteotomy in treating hallux valgus. *Clin Biomech (Bristol, Avon)* 2010; 25: 721-7. [\[Crossref\]](#)
17. Vienne P, Favre P, Meyer D, Schoeniger R, Wirth S, Espinosa N. Comparative mechanical testing of different geometric designs of distal first metatarsal osteotomies. *Foot Ankle Int* 2007; 28: 232-6. [\[Crossref\]](#)
18. Helmy N, Vienne P, Von Campe A, Espinosa N. Treatment of hallux valgus deformity: Preliminary results with a modified distal metatarsal osteotomy. *Acta Orthop Belg* 2009; 75: 661-70.
19. Acevedo JI, Sammarco VJ, Boucher HR, Parks BG, Schon LC, Myerson MS. Mechanical comparison of cyclic loading in five different first metatarsal shaft osteotomies. *Foot Ankle Int* 2002; 23: 711-6. [\[Crossref\]](#)
20. Nyska M, Trnka HJ, Parks BG, Myerson MS. Proximal metatarsal osteotomies: a comparative geometric analysis conducted on sawbone models. *Foot Ankle Int* 2002; 23: 938-45. [\[Crossref\]](#)
21. Popoff I, Negrine JP, Zecovic M, Svehla M, Walsh WR. The effect of screw type on the biomechanical properties of SCARF and crescentic osteotomies of the first metatarsal. *J Foot Ankle Surg* 2003; 42: 161-4. [\[Crossref\]](#)
22. Trnka HJ, Parks BG, Ivanic G, et al. Six first metatarsal shaft osteotomies: mechanical and immobilization comparisons. *Clin Orthop Relat Res* 2000; 381: 256-65. [\[Crossref\]](#)
23. McCluskey LC, Johnson JE, Wynarsky GT, Harris GF. Comparison of stability of proximal crescentic metatarsal osteotomy and proximal horizontal "V" osteotomy. *Foot Ankle Int* 1994; 15: 263-70. [\[Crossref\]](#)
24. Shaw N, Wertheimer S, Krueger J, Haut R. A mechanical comparison of first metatarsal diaphyseal osteotomies for the correction of hallux abducto valgus. *J Foot Ankle Surg* 2001; 40: 271-6. [\[Crossref\]](#)