



Case Report

Cerebral and Cardiac Locations of Hydatid Cyst in A Pregnant Case Presenting With Acute Stroke and MR Images Like Intracranial Tumor

Sırma GEYİK¹, Aylin AKÇALI¹, Murat GEYİK³, Mehmet Ali ELÇİ¹, Yasemin EKMEKYAPAR FIRAT¹, Akif ŞİRİKÇİ²

¹Gaziantep University, Faculty of Medicine, Neurology, Gaziantep, Türkiye ²Gaziantep University, Faculty of Medicine, Radiology, Gaziantep, Türkiye ³SANKO University, Faculty of Medicine, Neurosurgery, Gaziantep, Türkiye

Summary

Heart and brain involvement in a case is very rare in echinococcus cysts disease. A 23 year old, 28 weeks pregnant women admitted with acute right hemihypoesthesia and headache to the emergency department. Venous sinuse thrombosis was the initial diagnosis of the patient until the further investigations were performed. But the MRI scans and ECO revealed hydatid cyst. Serological tests for echinococcosis were positive. This case is worthfull with the right atrial and brain involvement of echinococcosis clinic presenting as a cerebral venous thrombosis in pregnancy and different cranial MR imagines like intracranial tumor.

Key words: Hydatid cyst, Pregnancy, Cardiac, Cranial

Akut Svo Bulgusu ile Başvuran Mr Görüntüsü İtrakranial Tümöre Benzeyen Kardiyak ve Serebral Kist Hidatikli Gebe Olgusu

Özet

Ekinokok hastalığında kalp ve beyin tutulumu oldukça nadirdir. 23 yaşında ve 28 haftalık gebe hasta, acil servise akut sağ hemihipoestezi ve başağrısı şikayeti ile kabul edildi. Görüntüler elde edilinceye kadar, venöz sinüs trombozu ön tanımız idi. Ancak MRG ve EKO incelemeleri hidatik kist tanısı düşünüldü. Serolojik testlerde ekinokok pozitif saptandı. Bu olgu, gebe bir hastada venöz sinüs trombozunu taklit eden sağ atrium ve kranial ekinok tutulumu olması,kranyal MR görüntülerinin intrakranial tümöre benzemesi sebebiyle sunulmaya değer bulunmuştur.

Anahtar Kelimeler: Kist hidatik, Gebe,Kardiyak, Kranial

INTRODUCTION

Hydatid cysts are commonly observed in countries raising livestock. Prevalence is estimated to be 1:2000 and incidence is estimated to be around 2:100000 in Turkey⁽¹⁹⁾. 99% of the cases are caused by

Echinococcus granulosus, whereas Echinococcus multilocularis rarely (1%) leads to occurrence of disease⁽³⁾. Human is the incidental intermediate host particularly when the parasite eggs originated from infected sheep and dog are entered into human body in result of

consumption of contaminated drinking water and meat⁽¹⁷⁾. Parasites are found in the liver, lung, soft tissues, heart, pericardium, muscles and subcutaneous tissues at the rates of 50-70%, 11-17%, 2.4-5.3%, 0.5-3%, 5% and 0.5-4.7%, respectively. However, they can be detected in any region of the body^(19,3,24).

Hydatid cyst may be asymptomatic as well as its general effects such as loss of appetite, weight loss, fatigue, recurrent urticaria and angioedema⁽¹³⁾. In addition, it may become apparent with various symptoms depending on the location of cysts. Hydatid cyst may remain silent for years and be captured incidentally by imaging examinations in asymptomatic cases. Hydatid cyst cases may also involve the central nervous system. However, this occurs rarely. These cases are responsible for around 2% of the intracranial masses⁽¹⁴⁾. The most frequent location of the parasite in brain is middle cerebral artery⁽¹⁵⁾. Although less often, spinal placement may also be observed⁽²²⁾. Hydatid cyst is also observed rarely in pregnancy⁽²⁴⁾. Radiology and ELISA are used in the diagnosis of disease. Specific antigen or immunocomplex are detected to be positive in 90% of the patients by ELISA method, however, serological tests may not be sufficient in terms of diagnosis for cerebral cysts^(18,1). Cranial Tomography (CT) and Cranial Magnetic Resonance Imaging (MRI) are used in cerebral cases, while ECHO is used in cardiac involvements for diagnosis of disease.

CASE PRESENTATION

A 23-year-old multipar 28 week pregnant woman was admitted to our clinic with a seizure and she had been complaining of right hypoesthesia and headache for the last two days. Her past medical and family history was unremarkable. Her systemic

examination was normal. Right hemihypoesthesia was observed in neurological examination. Her ESR was high and the other routine laboratory investigations were normal. Venous sinus thrombosis was the initial diagnosis of the patient until the further investigations were performed. Cranial MRI T1 weighted images showed multicompartmental cystic lesion with peri lesional hyperintensities corresponding to vasogenic edema in the frontoparietal lobes (Figure 1). Postcontrast T1 weighted images showed a smooth capsular enhancement in the lesion (Figure 2). Echocardiography showed a 3.1×1.7 cm cystic mass in the interatrial septum of the right atrium, there was mild-moderate mitral regurgitation (Figure 3). Transesophageal echocardiogram revealed multiple cystic lesions and observed a handle and mobile small cystic lesion that originating from the big lesion. These findings were consistent with cardiac Hydatid cyst. The diagnostic of hydatidosis was confirmed by a serologic test for *Echinococcus granulosus*. Indirect agglutination test of echinococcosis was positive (1/1280). No pathological findings were observed in chest computed tomography, abdominal and pelvic ultrasonography.

She had cesarean section primarily. After that cardiac surgery was performed. Surgical treatment included puncture and aspiration of cyst content following sterilization with hypertonic saline solution (Figure 4). Albendazole therapy (400 mg/day) was given after surgery. Control echocardiography was normal. Six month follow up control T2 weighted MR images showed no changes in cystic lesion and periedema (Figure 5). Hence the diagnosis of the cystic mass is confirmed as cerebral hydatid cyst disease.

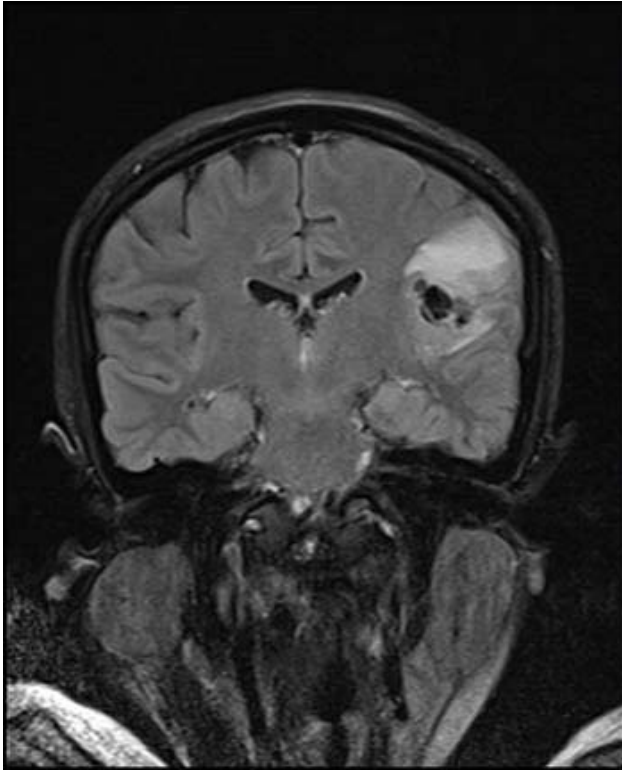

Figure 1: MR T1W coronal image of brain showing multicompartmental cystic lesion with peri lesional hyperintensities corresponding to vasogenic edema in the frontoparietal lobes

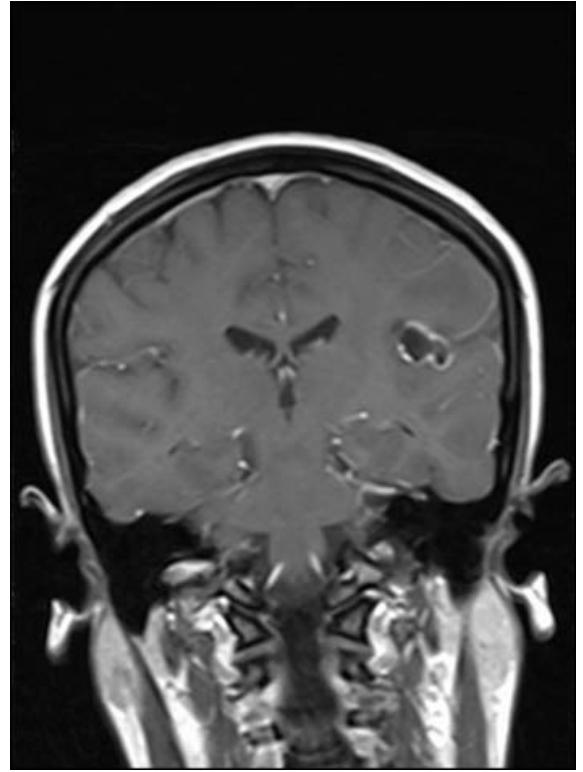


Figure 2: Postcontrast T1 weighted coronal images showing a smooth capsular enhancement in the lesion

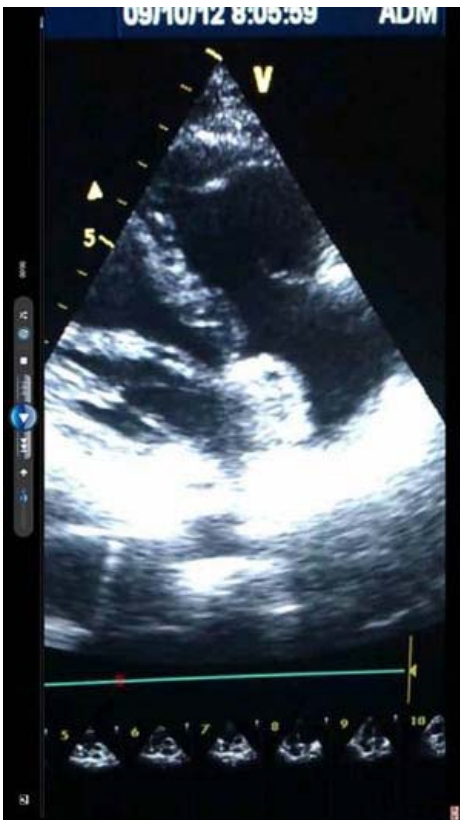

Figure 3: Echocardiography showed a 3.1×1.7 cm cystic mass in the interatrial septum of the right atrium, there was mild-moderate mitral regurgitation.

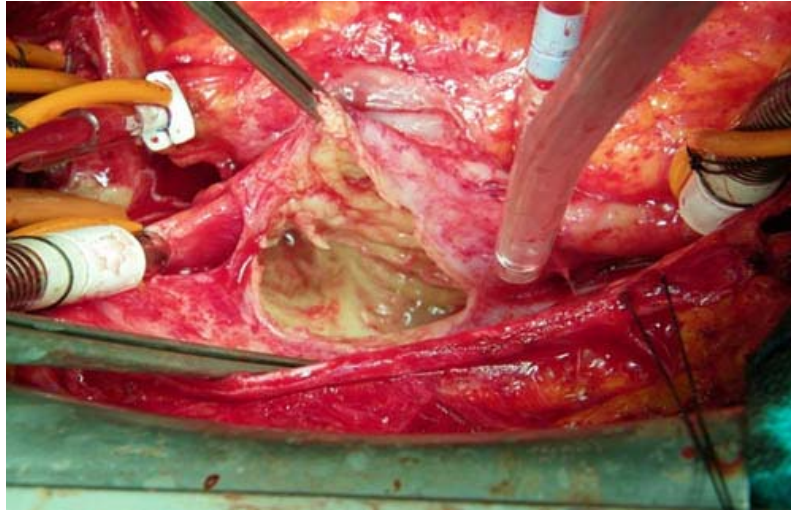


Figure 4: The view of cystic membrane in the interatrial septum

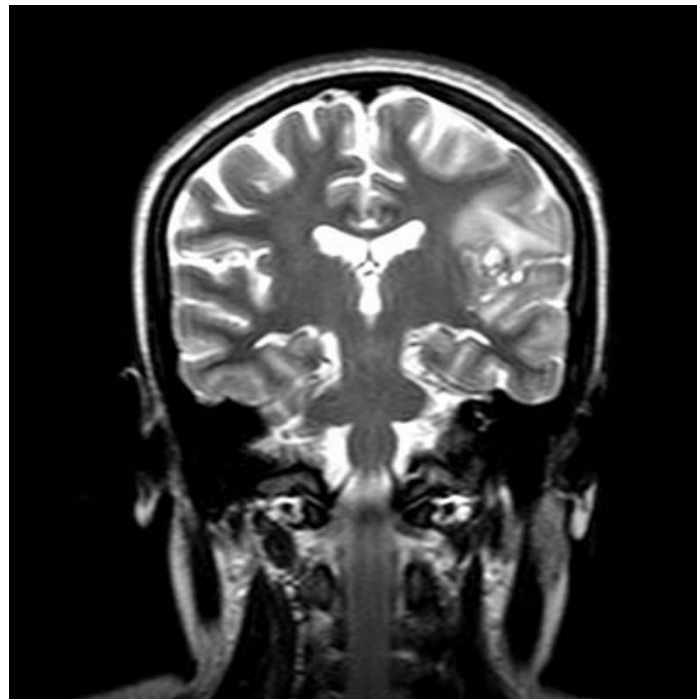


Figure 5: Control (six months later) T2 W coronal MR images showing no changes in cystic lesion and periedema

DISCUSSION

Acute neurological symptoms in a pregnant woman could be caused by exacerbation of a preexisting neurological condition, by initial presentation of a non-pregnancy-related problem, or by new onset neurological conditions that occur uniquely or with increased frequency just during pregnancy. Cerebral venous thrombosis in pregnancy is the most common cerebrovascular incident during the puerperium⁽⁸⁾. Clinical manifestations consist of headache, vomiting, focal or generalized seizures, confusion, blurred vision, focal neurologic deficits, and altered level of consciousness like in this case.

The first hydatid cyst case in heart has been reported by Griesinger in 1846⁽²⁾. Cardiac involvement is observed in more than 50% of the cases with systemic diffusion⁽⁹⁾. Parasite frequently enters into left ventricle in solid state through coronary circulation, lymphatic vessels, pulmonary veins and patent foramen ovale. Left ventricular myocardium is a common placement region (50-60%) in cardiac involvement as it gets more blood. Placement is observed less often in right ventricle (15%) and particularly in interventricular septum (5-9%). The most uncommon placement site of the cyst is right atrium with 3-4%^(2,7,20). Also in our case, cyst was observed in right atrium, as the most uncommon cardiac placement site.

78% of the patients with cardiac hydatid cyst are known to be symptomatic⁽²⁾. Cysts located in intraventricular septum may cause syncope episodes by leading to atrioventricular block. Cyst may cause to obstruction by residing at the outlet of right ventricle or lead to constrictive pericarditis in result of the cyst rupture in ventricular wall. Cyst may also lead to angina, valve dysfunction, pericardial reaction, pulmonary and systemic embolism, pulmonary hypertension and anaphylactic

reaction depending on its location in the heart. Cysts causing pressure on coronary arteries may result in myocardial infarction^(9,20,10). For patients admitted with such complaints, mediastinal tumors, other cardiac tumors and cysts, pericardial cysts and ventricular aneurysm should be considered in differential diagnosis. Transthoracic and transesophageal echocardiography is more effective than CT and MRI in diagnosis of cases with cardiac hydatid cyst, however, CT and MRI may be used in non-cardiac regions^(9,7). Another complication of cardiac cyst is rare cerebral ischemic infarction. Cerebrovascular infarctions occur in result of entering of metastatic cysts into systemic circulation through aorta. Another complication of central nervous system leads to neurological symptoms in result of parenchymal compression caused by mechanical effects exerted by cysts frequently at atypical locations, which occur as a result of entering of cysts into brain through blood circulation⁽²¹⁾. In children, initial complaints of presentation are frequently symptoms of increased intracranial pressure due to its intracranial space occupying effect, whereas focal findings such as hemiparesis, epileptic episodes, sensory disorders, cranial nerve involvement and speech disorders are observed more commonly in adults^(21,16,11). Cerebral hydatid cyst is rare accounting for 2-3% of all hydatid cyst cases, while spinal involvement is observed less commonly with < 1%⁽¹¹⁾. It tends to be most frequently located in middle cerebral artery region of the brain and usually involves in temporal, parietal and occipital regions^(15,11). If intracranial hydatid cyst directly enters into brain with infestation, it referred to as primary infestation, while it is known as secondary infestation if resulting from the surgical rupture of spontaneous, traumatic and primary intracranial cyst of another focus⁽⁶⁾. Primary intracranial cysts are usually

solitary, whereas the secondary cysts are multiple⁽²³⁾. Turgut et. al., in their literature compilation, determined only 6 (9%) cardiac-originated cerebral embolization from 68 metastatic cerebral hydatid cyst cases⁽²¹⁾. CT and MRI are used in the diagnosis of cerebral hydatid cyst. El-Shamam et al. classified hydatid cyst based on the presence or absence of surrounding perifocal edema and contrast enhancement. The first group with no surrounding edema or evidence of contrast enhancement and reconsidered simple cyst. The second group with varying degrees of perifocal edema and contrast enhancement is considered as complicated or infected cysts. The second group is showed more tendency of recurrence after surgery⁽⁵⁾. Due to this classification the T2WI of the patient showed multiple cysts in the fronto-temporal regions with T2-FLAIR hyper intense area of surrounding perifocal edema. Post contrast MR of the patient showed perilesional enhancement as in the second group.

Surgery is recommended in cases of cardiac hydatid cyst to prevent embolism⁽¹²⁾. Albendazole and surgery are recommended in treatment of cerebral hydatid cyst⁽¹⁵⁾. Surgery is required in non-ruptured intracranial hydatid cysts. Rupture may occur during surgery of giant hydatid cysts followed by recurrence⁽⁴⁾. Hydatid cysts are observed rarely in pregnancy. Its incidence in pregnancy is between 1:20000 and 1:30000⁽²⁴⁾. Pregnancy is considered to be a predisposing factor for brain metastasis in hydatid cyst disease⁽¹⁶⁾. Hydatid cyst may grow due to suppression of cellular immunity and placental steroid secretion during pregnancy⁽¹⁹⁾. Use of antihelminthic drugs as medical therapy in pregnancy is relatively contraindicated because of teratogenic effects in the first trimester. However, they may be used safely in second and third trimester. Teratogenic effects of these drugs in early stages of pregnancy have been determined in animal studies^(19,24,23).

In conclusion, hydatid cysts are observed relatively common in our country. However, it is worth to present a case acutely developed in a pregnant patient and resulted in cardiac-located hydatid cyst with cerebral metastasis. Imaging studies showed an unusual contrast and suggested the space-occupying lesion. This case was not only surprising because of the imaging findings, but also it was a fully treatable emergency situation that involved three distinct specialties: neurology, cardiology and obstetrics.

Correspondence to:

Sırma Geyik

E-mail: drsirmageyik@hotmail.com

Received by: 27 November 2013

Revised by: 16 December 2013

Accepted: 03 May 2014

The Online Journal of Neurological Sciences (Turkish) 1984-2014

This e-journal is run by Ege University Faculty of Medicine,

Dept. of Neurological Surgery, Bornova, Izmir-35100TR

as part of the Ege Neurological Surgery World Wide Web service.

Comments and feedback:

E-mail: editor@jns.dergisi.org

URL: <http://www.jns.dergisi.org>

Journal of Neurological Sciences (Turkish)

Abbr: J. Neurol. Sci.[Turk]

ISSNe 1302-1664

REFERENCES

1. Abbassioun K, Amirjamshidi A. *Diagnosis and Management of Hydatid Cyst of the Central Nervous System: Part 1: General Considerations and Hydatid Disease of the Brain. Neurosurgery Quarterly.* 2001;11:1-9.
2. Aytacı A, Türkoğlu H, Bilal MS, Akçevin A, Bakay C, Sarıoğlu T. et al: *Kardiyak hidatik kist hastalığı ve cerrahi tedavisi:6 şahsi vakaya dayanan derleme. Türk Kardiyol Dern. Arş.* 1991;19:340-4.
3. Çörtelekoğlu AT, Beşirli K, Yüceyar L, Bozkurt K; Kaynak K, Tüzün H, Sayın AG. *Atipik yerleşimli kist hidatik. Türk göğüs kalp damar cerrahisiderg.*2003;11:195-7.
4. Çullu N, Geter S, Karakaş E, Karakaş Ö, Çelik B, Çalık M: *Primer Dev İntrakranial Hidatik Kist: Bir Olgu Sunumu. Causa Pedia.* 2013;2:331.
5. El Shamam, Tala Amer, m. Abo El-Atta: *Magnetic resonance imaging of simple and infected hydatid cysts of the brain. Magnetic Resonance Imaging.*2001;19(7):965-74.
6. Furtado SV, Visvanathan K, Nandita G, Reddy K, Hegde AS. *Multiple fourth ventricular hydatidosis. Case Reports Journal of Clinical Neuroscience* 2009;16:110–2.
7. Göz M, Çakır Ö, Kılınc N,Eren MN. *A case of multi vesicular cardiac hydatid cyst with cerebral involvement. Turkish J Thorac CardiovascSurg* 2008;16(3):186-8.
8. J. S. Jeng, S. C. Tang, and P. K. Yip. *Incidence and etiologies of stroke during pregnancy and puerperium as evidenced in Taiwanese women. Cerebrovascular Diseases* 2004;18:290-295.
9. Katewa A, Vaideeswar P, Khandekar VJ, Sajid S, Jawale RM, Agrawal NB, et al: *Isolated pericardial and intracardiac hydatidosis: presentation as congestive cardiac failure and fatal pulmonary embolism. Cardiovascular Pathology* 2009;18:114–8.
10. Keçelgil HT, Kolbakır F, Kalaç R, Erk K. *Bir Kardiyak Kist Hidatik Olgusu ve Cerrahi Tedavisi. GKD Cer. Derg.* 1995; 3:48-50.
11. Limaiem F, Bellil S, Bellil K, Chelly I, Mekni A, Khaldi M, et al. *Primaryhydatidosis of the central nervous system: A retrospectivestudy of 39 Tunisian cases. Clinical Neurology and Neurosurgery.* 2010;112: 23–8.
12. Miralles A, Bracamonte L, Pavie A, Bors V, Rabago G, Gandjbakhch I, et al: *Cardiac echinococcosis. Surgical treatment and results. J Thorac Cardiovasc Surg.* 1994;107:184-90.
13. Mousavi SR, Samsami M, Fallah M, Zirakzadeh H. *A retrospective survey of human hydatidosis based on hospital records during the period of 10 years. Journal of Parasitic Diseases.* 2012;36:7-9.
14. Nourbakhsh A, Vannemreddy P, Minagar A, Toledo EG, Palacios E, Nanda A: *Hydatid disease of the central nervous system: a review of literature with an emphasis on Latin American countries. Neurol Res.* 2010;32:245- 51.
15. Oscar H, Brutto OH. *Infections and Stroke. Seminars in Cerebrovascular Disease and Stroke.* 2005;5:28-39.
16. Öztürk F, Onur MR, Yıldırım H, Bahçecioğlu İH: *Beyin Tümörünü Taklit Eden Serebral Alveolar Ekinokok. Fırat Tıp Dergisi.* 2011; 16(3):156-9.
17. Romig T. *Epidemiology of echinococcosis: Langenbecks Arch Surg.* 2003;388:209-17.
18. Sbihi Y, Rmiqui A, Rodriguez- Cabezas MN, Orduna A, Rodriguez- Torres A, Osuna A. *Comparative sensitivity of six serological tests and diagnostic value of ELISA using purified antigen in hydatidosis. J Clin Lab Anal* 2001; 15: 14-8.
19. Tertemiz KC, Gökçen B, Önen A, Akkoçlu . *Gebelik ve kist hidatik. Tüberküloz ve toraks dergisi* 2008;56(1):96-9.
20. Tetik O, Yilik L, Emreca B. *Gianthydatidcyst in the inter ventricular septum of a pregnant woman. Text Heart Inst J.* 2002; 29:333-5.
21. Turgut M, Bayülkem K. *Cerebrovascular occlusive disease: hydatidosis.: Child's Nerv. Syst.* 1998;14:697–9.
22. Yazdani N, Basam A, Heidarali M, Sharif Kashani S, Hasibi M, Mokhtari Z. *Infratemporal hydatid cyst: a case presenting with blindness. J Laryngol Otol.* 2010;124:456-9.
23. Yılmaz N, Kıymaz N, Etlik O, Yazıcı T: *Primary hydadedid cyst of the brain during pregnancy. NeurolMedChir.* 2006; 46:415-7.
24. Zeybek B, Ergenoglu AM, Yenieli AÖ, Ulukuş M: *Hepatic hydatid disease during pregnancy. Ege Journal of Medicine.* 2010; 49(3):197-9.