

# ERİŞKİN ERKEK MEMESİNDE İNTRADUKTAL KARSİOMLA BİRLİKTEKİ GÖSTEREN İNTRAKİSTİK PAPİLLER KARSİNOM: NADİR BİR OLGU

## Intracystic Papillary Carcinoma in Association with Intraductal Carcinoma in Adult Male Breast: A Rare Case Report

Erdal UYSAL<sup>1</sup>, Mehmet DOKUR<sup>2</sup>, Mesut SİPAHİ<sup>3</sup>, Mehmet SÖKÜCÜ<sup>4</sup>, Mehmet A. İKİDAĞ<sup>5</sup>

### ÖZET

Meme kansinoları erkeklerde daha az görülür. Ayrıca memede intrakistik papiller kansinom ve intraduktal kansinom birlikteliği son derece nadir. İntrakistik papiller kansinometyolojisinde çok sayıda factor suçlanmıştır. İntrakistik papiller kansinomun ultrasonografik bulguları tipiktir. Eksizyonel biyopsi ile beraber mümkünse immunohisto kimyasal boyama yapılması mikroskopik tanı için önemlidir. İntrakistik papiller kansinoların prognozu, intraduktal kansinolarla göre daha iyidir ve invazivolarında local yayılım görülür. İntrakistik papiller kansinom tedavisinde invazyon belirtileri varsa, adjuvant kemoterapi ile beraber radikal mastektomi önerilir. Hormono terapinin yararı halen tartışmalıdır.

Bu makalede, hastane mizin acil servisine sağ memesinde ağrısız bir kitle ile başvuran 74 yaşındaki bir erkek hastanın klinik bulguları, tanı ve tedavi prensipleri güncel literature ışığında tartışıldı.

**Anahtar kelimeler:** *Meme kanseri; Erişkin erkek; İntrakistik papiller kansinom; İntraduktal kansinom*

### ABSTRACT

Breast carcinomas are less common in males. Also intracystic papillary carcinoma and intraductal carcinoma are seen together, this is extremely rare in breast in men. Many factors have been implicated in etiology of intracystic papillary carcinoma. Ultrasonographic findings of intracystic papillary carcinoma is typical. It is important to have excisional biopsy and perform immunohistochemical staining-if possible along under microscopy. The prognosis of intracystic papilloma is relatively better than intraductal carcinoma and its spread is mostly local if invasive. In the treatment of intracystic papillary carcinoma, if there are signs of invasions of radical mastectomy with adjuvant radiotherapy treatment is recommended. The benefits of hormone therapy are still controversial.

In this article, a 74 year-old male patient who noticed a painless mass in his right breast and incidentally admitted to our emergency department and this patient's clinical findings, diagnosis and treatment principles are discussed in the current literature.

**Key words:** *Breast cancer; Adult male; Intracystic papillary carcinoma; Intraductal carcinoma*

<sup>1</sup>Sanko üniversitesi Tıp Fakültesi,  
Genel Cerrahi Anabilim Dalı,  
Gaziantep

<sup>2</sup>Sanko üniversitesi Tıp Fakültesi,  
Acil Bölümü, Gaziantep

<sup>3</sup>Bozok Üniversitesi Tıp Fakültesi,  
Genel Cerrahi Anabilim Dalı,  
Yozgat

<sup>4</sup>Sanko üniversitesi Tıp Fakültesi,  
Patoloji Dalı, Gaziantep

<sup>5</sup>Sanko üniversitesi Tıp Fakültesi,  
Radyoloji Anabilim Dalı,  
Gaziantep

Erdal UYSAL, Yrd.Doç. Dr.  
Mehmet DOKUR, Yrd.Doç. Dr.  
Mesut SİPAHİ, Yrd. Doç. Dr.  
Mehmet SÖKÜCÜ, Dr.  
Mehmet Ali İKİDAĞ, Yrd. Doç. Dr.

#### İletişim:

Sanko üniversitesi Tıp Fakültesi,  
Genel Cerrahi Anabilim Dalı  
İncilipinar Mah. AliFuat Cebesoy  
Bulv. No: 45 27090, Gaziantep  
Tel: +90 3422115000

#### e-mail:

drerdaluysal@hotmail.com

Geliş tarihi/Received: 26.04.2015

Kabul tarihi/Accepted:07.09.2015

Bozok Tıp Derg 2016;1(1):68-71  
Bozok Med J 2016;1(1):68-71

## INTRODUCTION

Intracystic papillary carcinoma (IPC), which contains a cystic space surrounded by a fibrous capsule and forms the papillary type of ductal carcinoma, is defined as a lesion (1). It is a rare clinical condition. It has been reported in a few cases in the English literature (2).

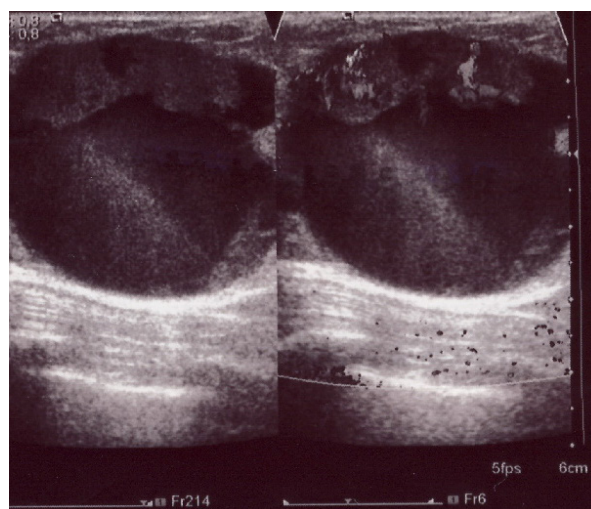
The mammary carcinomas, rarely seen in males, account for 0.6% of all mammary carcinomas and account for less than 1% of all malignancies and IPC represents only 5-7.5% of all male breast carcinomas respectively (3). The etiology of IPC is still not clear; many hormonal, congenital, genetic and traumatic factors were held responsible. In the genetic diagnosis of IPC, the loss of chromosome 16q is an important marker (4). The vast majority of IPC's are non-invasive. IPC is usually unilateral and most IPC cases in male breasts are non-invasive. The prognosis of IPC is good for elders (5). In a study conducted on IPC's, the survival rate was reported to be 100% for 10 years and the recurrence rate was reported as 96% for 2 years, and 76% for 10 years, respectively (6). However, a portion of the IPC's has been reported to be invasive. Invasions mostly occur in local lymph nodes as close metastasis style (7). Myoepithelial layer are not observed in invasive IPC's very often (8). During ultrasonography, observing hypoechoic components in the cystic structures is an important radiological finding for pre-diagnosis of IPC. Incisional biopsy is needed for definitive diagnosis. In the biopsy, intense mitotic activity of papillary structure is recognized (9). Total mastectomy with axillary dissection is recommended in treatment (10). In invasive IPC, adjuvant radiation therapy can also be applied after surgical treatment. There is not enough evidence for the efficacy of hormonal therapy (11).

In this case report, it has been aimed to present our findings found in our patient, who is diagnosed with IPC intraductal carcinoma rarely seen in male breast, and share our clinical experiences. Besides being quite rare especially in male breast, observing with intraductal carcinoma makes the rarer.

## CASE

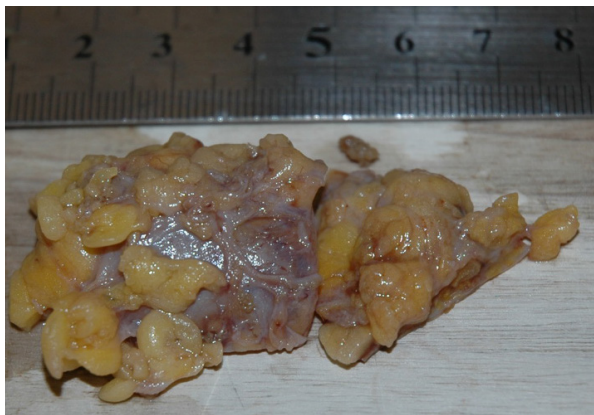74-year-old male patient has admitted to our

emergency department with a hard mass noticing, which is growing for a year with no pain in his right breast. The only information received from the patient was history of hypertension. In the physical examination of the patient, an elliptical, rigid and a mobile mass was palpated in the upper inner and lower quadrant of right breast with 6x3 cm in size. In addition, palpable lymphadenopathy (LAP) was detected in the arm-pit on the same side. No pathological findings were found on the other breast after physical examination. Breast ultrasonography (US) was performed on the patient, who was consulted by the general surgery department. In the breast US of the patient, a single large cystic structure containing hypoechoic solid components (63x36 mm in size) was found in the right breast (Figure 1).



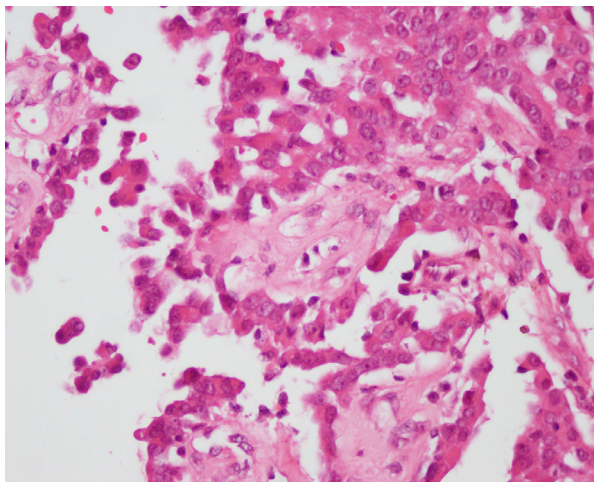
**Figure 1.** Ultrasonographic view of cystic breast tumour (hypo-echoic area with soft tissue echoes projecting from wall of the intracystic tumour. Ultrasonographic diameter measurement was 63.0x36.2 mm).

Modified radical mastectomy (MRM) was planned to be performed on the patient, who was pre-diagnosed with IPC. During operation this specimen excised was as about 60x35 mm in sizes. It also seemed like a hard and cystic mass with an outer surface surrounded by fat (Figure 2).



**Figure 2.** Macroscopic view of cystic breast tumor (about 60x35 mm in size).

Histopathological examination showed the tumor composed of papillary and adenoid structures lined by columnar cells with cytological atypia around fibrovascular cores and these histopathological findings were compatible with intracystic papillary carcinoma and intraductal carcinoma (NOS Type) (Figure 3).



**Figure 3.** The tumor showing papillary structures lined by columnar atypical cells around fibrovascular cores (H&E stain, x200).

Immunohistochemical staining could not be performed due to limitations. There was no problem in the postoperative follow-up of the patient. The patient was referred to the oncology department for adjuvant therapy. Adjuvant radiotherapy was decided to be applied on the patient. The patient continues his follow ups in the 23rd month after the surgery without metastasis and recurrence.

## DISCUSSION

The frequency of incidence of mammary carcinomas varies in different regions of the world. The mammary carcinomas seen in males account are less than 1% among all breast cancer cases (12). IPC is observed more frequently in African-Americans than white Americans, whereas it is seen less in Japanese compared to Chinese, African, Egyptian and Jew people (7). IPC is more common in older women and has a good prognosis (13, 14). In our case, since our patient is old and male, it is a rare clinical entity for IPC. The patients with breast carcinoma may be incidentally encountered in the emergency departments. In our case, the patient has applied to the emergency department with a mass in his breast to be directed to a surgical department. There is a family history in some of the IPC cases. IPC is generally located close to the nipple with no pain as unilateral. IPC is well diagnosed radiologically (15). It is typical to see hypoechoic areas in the intracystic tumor during the breast US (9). In our case, there was no history of breast carcinoma in the family of our patient, but the breast US findings were found consistent with the literature in terms of inclusion of hypoechoic and cystic areas. IPC's are studied in 2 groups as invasive and non-invasive. IPC is also classified into 2 groups based on its relationship with intraductal carcinoma and invasive ductal carcinoma (7). The best-known type of IPC is invasive ones. In invasive IPC, myoepithelial layer is not encountered in immunohistochemical staining in general (2, 5). Immunohistochemical staining could not be performed in biopsy material of our case due to the limitations. Survival rates are better in IPC compared to other invasive carcinomas. Metastases usually occur in local lymph nodes (11).

The findings of our case, diagnosed with axillary lymphadenopathy intraoperatively, were consistent with the findings of local invasion. Distant metastases were not detected. In the treatment, segmental mastectomy, simple mastectomy and MRM can be performed depending on the patient and size of tumor. Adjuvant radiotherapy can be performed. There is not enough evidence for hormonal therapy (2, 16). Our patients underwent MRM followed by adjuvant radiotherapy. After an approximately 2-year follow-up, no clinical problems were seen including tumor recurrence. This case may be associated with good prognosis in invasive IPC's.

## CONCLUSION

IPC is a breast lesion rarely seen in males. In these patients; clinical, radiological and histopathological examinations are very important in the diagnosis of IPC. Excisional biopsy is very helpful for diagnosis. The choice of surgical treatment should be done in accordance with the patient, tumor size and presence of invasion. A good clinical follow-up is required for recurrence.

## REFERENCES

1. Akladios CY, Roedlich MN, Bretz-Grenier MF, Croce S, Mathelin C. Intracystic papillary carcinoma of the breast: a diagnostic challenge with major clinical impact *Anticancer Res.* 2014;34(9):5017-20.
2. Vagholkar K, Dastoor K, Gopinathan I. Intracystic papillary carcinoma in the male breast: a rare endpoint of a wide spectrum. *Case Rep Oncol Med.* 2013;2013:129353.
3. Anderson WF, Devesa SS. In situ male breast carcinoma in the Surveillance, Epidemiology, and End Results database of the National Cancer Institute. *Cancer.* 2005;104(8):1733-41.
4. Tsuda H, Uei Y, Fukutomi T, Hirohashi S. Different incidence of loss of heterozygosity on chromosome 16q between intraductal papilloma and intracystic papillary carcinoma of the breast. *Jpn J Cancer Res.* 1994; 85:992-96.
5. Muallaoglu S, Ozdemir E, Kutluay L. Intracystic papillary carcinoma of the breast in a male patient: a case report. *Case Rep Med.* 2012;2012:378157.
6. Solorzano CC, Middleton LP, Hunt KK, Mirza N, Meric F, Kuerer HM et al. Treatment and outcome of patients with

intracystic papillary carcinoma of the breast. *Am J Surg.* 2002;184(4):364-8.

7. Hariprasad P, Srinivas T. Intracystic papillary carcinoma of the breast in males: a case report and review of the literature. *J Clin Diagn Res.* 2013;7(3):568-70.
8. Wynveen CA, Nehhozina T, Akram M, Hassan M, Norton L, Van Zee KJ, Brogi E. Intracystic papillary carcinoma of the breast: An in situ or invasive tumor? Results of immunohistochemical analysis and clinical follow-up. *Am J Surg Pathol.* 2011;35(1):1-14.
9. Lam WW, Tang AP, Tse G, Chu WC. Radiology-Pathology conference: papillary carcinoma of the breast. *Clin Imaging.* 2005;29(6):396-400.
10. Olu-Eddo AN, Ohanaka CE. Niger Postgrad Med J. Intracystic papillary carcinoma of the breast in a Nigerian male: case report. 2008;15(4):270-1.
11. Stamatakis M, Stefanaki C, Stasinou T, Papantoni E, Alexiou I, Kontzoglou K. Intracystic Papillary Carcinoma of the Breast in Males. In Search of the Optimal Treatment for this Rare Disease. *Breast Care (Basel).* 2011;6(5):399-403.
12. Kamyab A, Kasmikha Z, Singhi U, Jacobs MJ. Intracystic papillary carcinoma with associated intraductal carcinoma of the breast in a male. *Am Surg.* 2011;77(12):E267-8.
13. Sun Y, Howard-McNatt M. Intracystic papillary carcinoma of the breast in a male patient. *Am Surg.* 2014;80(3):E84-5. Review.
14. Ingle SB, Hinge Ingle CR, Murdeshwar HG, Adgaonkar BD. Unusual case of insitu (intracystic) papillary carcinoma of breast. *World J Clin Cases.* 2013;1(7):227-9.
15. Wang H, Li F, Luo B. Breast intracystic papillary carcinoma. *Breast J.* 2011;17(6):676-7.
16. Fayanju OM, Ritter J, Gillanders WE, Eberlein TJ, Dietz JR, Aft R et al. Therapeutic management of intracystic papillary carcinoma of the breast: the roles of radiation and endocrine therapy. *Am J Surg.* 2007;194(4):497-500.