

# The surgery and early postoperative radicular pain in cases with multifocal lumbar disc herniation

Murat Ulutaş, MD<sup>a,\*</sup>, Kadir Çınar, MD<sup>a</sup>, Mehmet Seçer, MD<sup>b</sup>

## Abstract

Persistence of postoperative radicular pain after surgery for multifocal disc herniation (MFDH) is a clinical problem. This study aims to evaluate the effects of a combined treatment approach compared with unilateral stabilization on early postoperative radicular pain in patients with MFDH.

Age, sex, level of operation, clinical findings, and radicular pain visual analogue scale (VAS) scores before surgery in the early postoperative period and at 3 months after surgery were retrospectively reviewed for 20 cases of multifocal lumbar disc herniation. The combined approach (translaminar and far lateral) was used for 13 cases. Seven cases underwent transforaminal lumbar interbody fusion (TLIF) and unilateral transpedicular stabilization following total facetectomy.

The mean age of the sample was  $49.4 \pm 10.1$  years and the female-to-male ratio was 8:12. The mean VAS scores for radicular pain in cases treated with the combined approach were 8.2, 4.07, and 2.3 in the preoperative and early postoperative periods and 3 months after surgery, respectively. The mean score for radicular pain improved by 50.4% in the early postoperative period and by 72% in the late postoperative period. The mean VAS scores for radicular pain in cases who underwent TLIF and unilateral stabilization after facetectomy were 8.4, 2.1, and 1.4 in the preoperative and early postoperative periods and 3 months after surgery, respectively. The mean VAS score for radicular pain improved by 75% in the early postoperative period and by 83.3% in the late postoperative period.

The combined approach is an effective alternative in cases with MFDH. TLIF and unilateral segmental stabilization provide substantial decompression and eliminate mechanical compression by conserving the height of the intervertebral foramen in the event that sufficient decompression is unable to obtain. We suggest that elimination of chemical mediators, particularly those causing pain in the dorsal ganglion, contributes to the absence of early radicular pain.

**Abbreviations:** DRG = dorsal root ganglia, LDH = lumbar disc herniation, MFDH = multifocal disc herniation, MRI = magnetic resonance imaging, TLIF = transforaminal lumbar interbody fusion, VAS = visual analogue scale.

**Keywords:** facetectomy, far lateral disc herniation, instability, multifocal disc herniation, radicular pain, unilateral stabilization

## 1. Introduction

Lumbar disc herniation (LDH) is classified as central, paracentral, far lateral, foraminal, and subarticular.<sup>[1,2]</sup> Radiculopathy is typically caused by paracentral disc herniation compressing a single nerve root.<sup>[3]</sup> Although rare, disc herniation causes neural compression in multiple compartments (multifo-

cal), resulting in biradicular symptoms.<sup>[1,2]</sup> Multifocal disc herniation (MFDH) compresses the dorsal root ganglia (DRG) in far lateral and foraminal components and is associated with more severe and persistent radicular pain compared with central and paracentral disc herniation.<sup>[1,3-5]</sup>

The nerve root can be compressed by the disc and/or a hypertrophic facet within or lateral to the intervertebral foramen or bone spurs originating from the vertebral endplate. The addition of facetectomy to the decompressive surgical procedure simply provides decompression of the spinal canal and intervertebral foramen but removing annulus may result in postoperative segmental instability due to the asymmetric disc collapse.<sup>[6,7]</sup> It has been reported that this condition might result in poor clinical outcomes.<sup>[6]</sup> Although translaminar midline (laminectomy, laminotomy, hemilaminectomy, subtotal, or total facetectomy), transmuscular far lateral, or a combination of these approaches, as well as an endoscopic procedure have been recommended in patients with far lateral, foraminal, and MFDH, there is currently no standardized surgical technique.<sup>[1,2,8,9]</sup> Radicular pain persisting in the postoperative period poses a clinical problem, resulting in dissatisfaction with the procedure in patients with MFDH. It was reported that MFDH was the most important cause of intractable radicular pain in the postoperative period in patients with MFDH.<sup>[6]</sup> This study aims to compare the effects of a combined treatment approach (translaminar and far

Editor: Somchai Amorniyotin.

Ethical approval was not required for this type of study at our institute.

The authors have no conflicts of interest to disclose.

<sup>a</sup>Sanko University Konukoglu hospital, Department of Neurosurgery Gaziantep, Turkey, <sup>b</sup>Dr Ersin Arslan Research and Training Hospital Department of Neurosurgery, Gaziantep, Turkey.

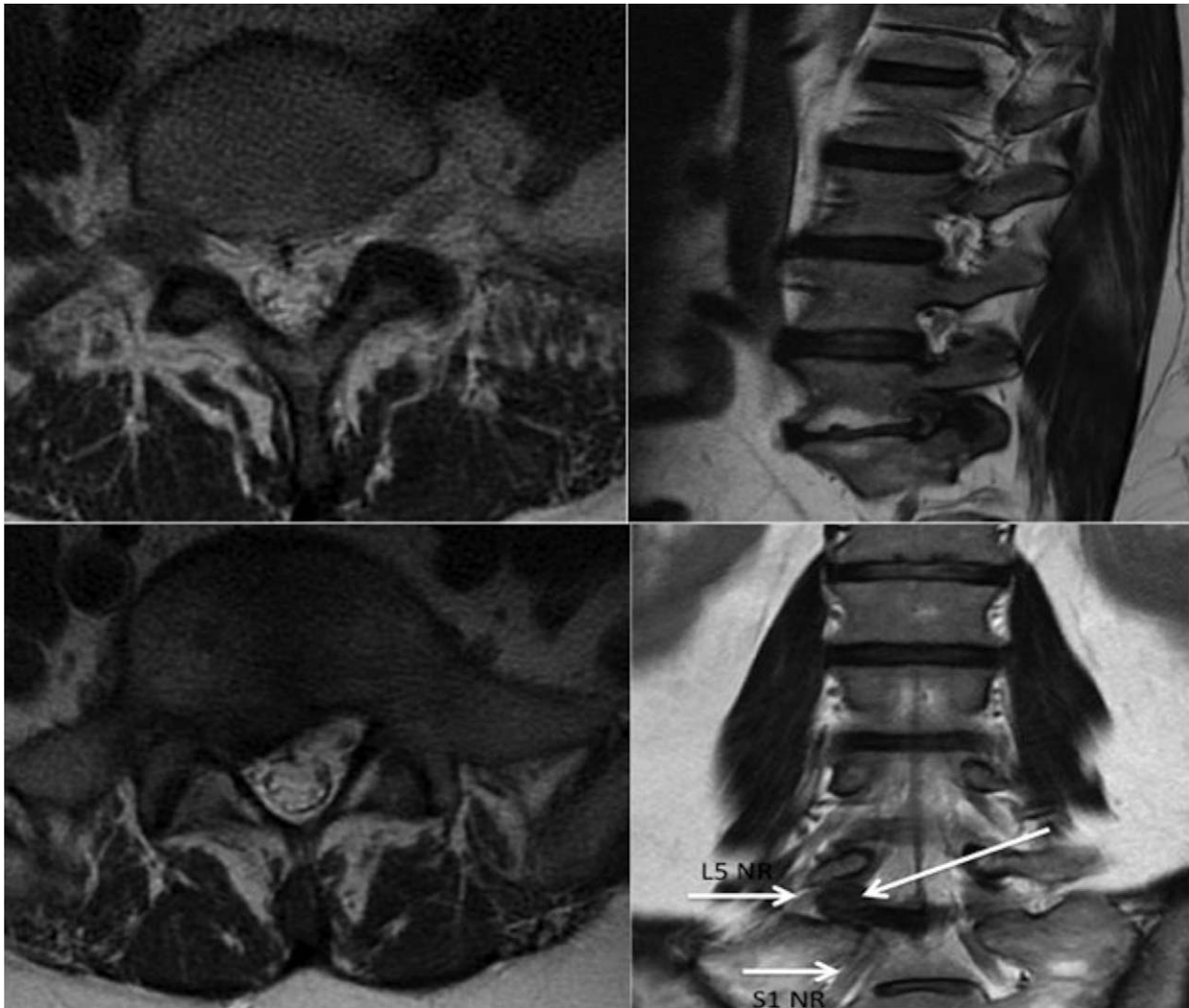\* Correspondence: Murat Ulutaş, Sanko University Konukoglu Hospital Department of Neurosurgery Gaziantep 27090, Turkey (e-mail: nrsrgn@yahoo.com).

Copyright © 2017 the Author(s). Published by Wolters Kluwer Health, Inc. This is an open access article distributed under the Creative Commons Attribution-NoDerivatives License 4.0, which allows for redistribution, commercial and non-commercial, as long as it is passed along unchanged and in whole, with credit to the author.

Medicine (2017) 96:9(e6238)

Received: 4 August 2016 / Received in final form: 4 February 2017 / Accepted: 6 February 2017

<http://dx.doi.org/10.1097/MD.0000000000006238>



**Figure 1.** Preoperative axial, sagittal, and coronal MRI scans of a case operated on using the combined approach due to foraminal and far lateral disc herniation (arrow). Herniated discs were displayed only on different sequences. This patient had biradicular pain and the neural roots (L5 and S1 nerve roots) were decompressed with combined approach. MRI = magnetic resonance imaging, NR=nerve root.

lateral) and unilateral stabilization for patients with MFDH on radicular pain in the early postoperative period.

## 2. Material and methods

### 2.1. Multifocal disc herniation

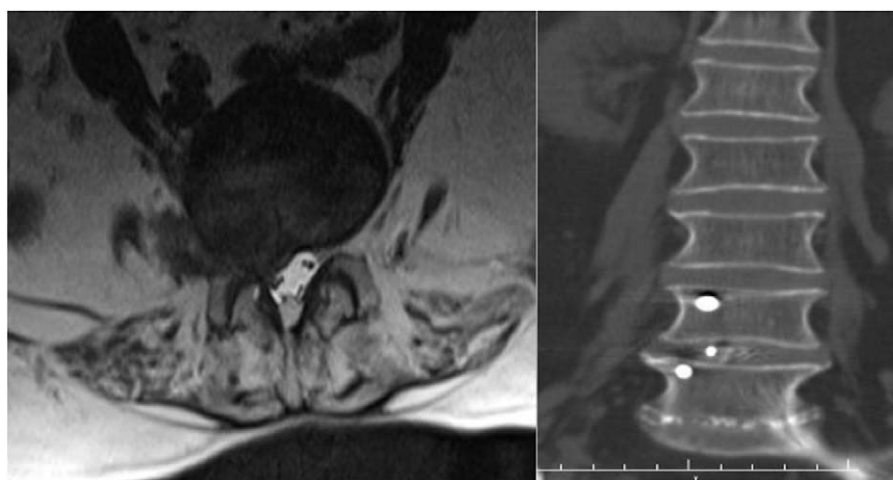
MFDH is a clinical condition arising from the LDH to the nerve root anatomically at the same level from the medial of pedicul and also from the lateral of the pedicul to the upper level nerve root in the foramen and the DRG. This clinical entity can be observed radiologically by magnetic resonance imaging (MRI). Disc protrusion appears as continuity toward the foramen in sagittal and axial sections. In particular, the disc in the foramen seen in the sagittal sections obscures adipose tissue and the extension to the medial of pedicle in the following sections (Figs. 1 and 2).

In the present study, location of the MFDH was defined as disc herniation involving 2 or 3 of the lateral (far lateral), medial (subarticular), and foraminal (pedicular level) zones. The most distinctive feature when compared with intracanalicular

or far lateral disc herniation is that MFDH causes biradicular pain by compressing both the nerve root and dorsal ganglion in the intervertebral foramen and the nerve root at the same level.

### 2.2. Patient population

The records of 20 patients who underwent surgery for MFDH at Sanko University Konukoğlu Hospital and Private Deva Hospital between 2003 and May 2016 were retrospectively reviewed. As this is a retrospective analysis, our ethic committee did not require patients' approval. The study included patients who did not have instability, did not previously undergo disc surgery, and had clinical follow-up for at least 3 months. Conditions causing severe and intractable radicular pain and the resulting nerve root compression were visualized using MRI. The information collected included age, sex, level of operation, clinical findings, and visual analogue scale (VAS) score for radicular pain before surgery, in the early postoperative period, and at 3 months after surgery (Table 1).



**Figure 2.** Preoperative axial MRI and postoperative CT images of a case that underwent TLIF and unilateral stabilization with total facetectomy due to subarticular, foraminal, and far lateral disc herniation and osteophyte. CT = computed tomography, MRI = magnetic resonance imaging, TLIF = transforaminal lumbar interbody fusion.

**2.3. Surgical technique**

All patients were given 1mg of intravenous midazolam 30 minutes before the operation as a premedication. Additionally, antibiotic (cefazolin 1g) was administered for prophylaxis. Before induction, 4 L/min oxygen (O<sub>2</sub>) was given through a mask for preoxygenation. Induction was then conducted using 1 microg/kg remifentanyl, 2 to 3 mg/kg propofol, and 0.5 mg/kg rocuronium intravenously. After induction and oxygenation, intubation was performed with an endotracheal tube with a cuff.

To maintain anesthesia, 0.25 microg/kg remifentanyl, 2% to 2.5% sevoflurane, and 4 L/min fresh gas flow (50% O<sub>2</sub>/50% air mix) were administered. Before extubation, 1 ampule of a nonsteroidal anti-inflammatory drug and 0.5 mg/kg tramadol were administered. After approximately 30 minutes in the recovery room, the patient was sent to the ward.

The patients were operated on in the prone position. The disc level was identified using fluoroscopy before making a 3 to 5 cm lateral to midline skin incision. The subcutaneous tissue was

**Table 1**  
Demographic characteristics, operation level, VAS radicular pain score, and surgical approaches for patients who underwent surgery for multifocal disc herniation.

	Age	Sex	Level	Preoperative VAS score	Early postoperative VAS score	VAS Score at postoperative 3 mo	Disc location	Surgical approach
1	50	M	L5S1	8	4	2	Sub-for	Combined
2	49	F	L5S1	9	5	3	Sub-for-far	Combined
3	50	M	L5S1	7	3	0	Sub-for	Combined
4	38	F	L4-5	7	4	2	For-far	Combined
5	66	M	L4-5	9	5	4	For-far	Combined
6	35	M	L3-4	9	5	3	For-far	Combined
7	44	F	L4-5	8	3	2	Sub-for	Combined
8	59	M	L4-5	8	3	2	For-far	Combined
9	38	F	L4-5	7	3	2	Sub-for	Combined
10	66	M	L4-5	9	4	3	For-far	Combined
11	48	M	L4-5	8	3	2	Sub-for	Combined
12	56	M	L4-5	8	6	3	Sub-for	Combined
13	35	F	L4-5	9	5	2	For-far	Combined
				8.2±0.8	4.07±1.03	2.3±0.9		
14	59	M	L4-5	8	2	1	Sub-for-far	TLIF+US
15	48	M	L4-5	8	2	2	Sub-for-far	TLIF+US
16	52	F	L3-4	8	2	2	For-far	TLIF+US
17	68	F	L3-4	9	2	1	Sub-for-far	TLIF+US
18	35	M	L3-4	9	2	1	Sub-for-far	TLIF+US
19	49	F	L3-4	9	3	2	Sub-for-far	TLIF+US
20	37	M	L2-3	8	2	1	Sub-for	TLIF+US
				8.4±0.5	2.1±0.4	1.4±0.5		

Thirteen cases underwent surgery using the combined approach, 7 cases underwent decompression surgery with facetectomy and TLIF+US. Using the combined approach, the mean score for radicular pain improved by 50.4% and 72% in the early and late postoperative periods, respectively. The mean VAS score for radicular pain improved by 75% and 83.3% in the early and late postoperative periods, respectively, in patients who underwent TLIF and unilateral stabilization due to facetectomy.

Far = far lateral, For = foraminal, MD = microdiscectomy, Sub = subarticular, TLIF = transforaminal interbody fusion, UN = unilateral stabilization, VAS = visual analogue scale.

dissected to the midline. After opening the fascia of the paravertebral muscle lateral to the multifidus muscle, finger dissection of the subperiosteal muscle was performed by reaching laterally to the facet and to the midline by subfascial dissection. The retractor was placed and the disc level was reexamined using fluoroscopy.

#### 2.4. Combined approach

The decision to use a combined approach instead of the classical interlaminar or extraforaminal lateral approach was based on the volume of MFDH. The translaminar approach was used for MFDH in the subarticular and foraminal zones. In the translaminar approach, disc protrusion was achieved from medial of the pedicle by removing less than half of the facet joints together with classical laminotomy. Attempts were made to remove multiple degenerated disc fragments by drawing the fragments into the visual field of the microscope with the aid of a nerve hook. These discs were usually multifragmented and the foraminal zone was controlled with the far lateral approach. The extraforaminal approach was preferred for MFDH located in the foraminal and far lateral zones. The procedure was combined with the translaminar approach after the removal of the disc fragments and the foraminal zone was controlled from the medial direction. Other reasons for the combination of the translaminar and extraforaminal approaches were the observation of annular tears and removal of subligamentous disc fragments without entering the disc space. The height of the iliac wings was not a restriction for the far lateral approach in our cases with a herniated disc at the level of L5–S1.

#### 2.5. Facetectomy with unilateral stabilization and transforaminal lumbar interbody fusion

Each of all patients was tried to be performed by combined approach but inability to provide sufficient decompression using the combined approach for MFDH compressing the nerve roots exiting the spine at the same, or upper level necessitated large laminotomy or direct facetectomy to weaken the support from the pars interarticularis. Less extensive manipulation was performed in a large area near the nerve root and DRG in these patients. To obtain a wide surgery working area with facetectomy is facilitated to remove the herniated disc and end plate materials. Thus, the mechanical pressure, which causes pain, and the nucleus pulposus, which is the source of chemical mediator, are removed by effective decompression. Transforaminal lumbar interbody fusion (TLIF) and unilateral transpedicular stabilization was performed after discectomy to empty the disc space to correct iatrogenic segmental instability after decompression.

Patients who performed unilateral stabilization were given 0.5 mg/kg tramadol for the establishment of surgical pain control in early postoperative period. NSAID was ordered in discharge period. Patients who performed combined approach were given NSAID in both postoperative and discharge periods. However, tramadol was ordered for patients those who have persistent radicular pain were unable restored through NSAID in early postoperative period.

#### 2.6. Statistical analysis

The statistical analysis was performed using SPSS (Statistical Package for Social Sciences Inc, version 22.0, Chicago, IL).

Pearson correlation coefficients were used to evaluate the relationship between the surgical approaches (combined approach versus facetectomy and fusion) and early postoperative pain.  $\chi^2$  tests were used to compare preoperative and postoperative pain scores. A *P* value less than 0.05 was considered statistically significant.

### 3. Results

Twenty cases underwent surgery due to MFDH, and all patients had severe unilateral radicular pain. The procedural approach (translaminar or far lateral) was determined based on disc volume. In 13 cases, neural decompression was achieved by the removal of a herniated disc that occupied multiple compartments using the combined approach. The discectomy was not performed in these cases; only fragmentectomy was performed and the subligamentous disc fragments were removed. The combined approach failed to achieve sufficient neural decompression in 7 cases and these patients required more extensive laminotomy or facetectomy to weaken the support from the pars interarticularis. The presence of degenerative disc disease and a herniated disc that could not be removed single piece, or the presence of multifragmented disc herniation, osteophytes originating from the end plate and compressing the foramen accompanied with a herniated disc, and the need to perform a laminotomy large enough to weaken the isthmus support were factors that required facetectomy. In these cases, TLIF and unilateral transpedicular stabilization were performed due to iatrogenic segmental instability.

The mean age of the sample was  $49.4 \pm 10.1$  years. The female-to-male ratio was 8:12. The distribution of cases according to the disc level was as follows: L5–S1, 3 (15%); L4–5, 11 (55%); L3–4, 5 (25%); L2–3, 1 (5%). The herniated disc was located in the subarticular and foraminal zones in 6 cases (30%), foraminal and far lateral zones in 8 cases (40%), and foraminal, extraforaminal, and subarticular zones in 6 cases (30%).

The mean VAS score for radicular pain in cases treated with the combined approach was 8.2 in the preoperative period, 4.07 in the early postoperative period (first 1 week), and 2.3 three months after surgery ( $P < 0.001$ ). There was a significant improvement compared with the preoperative period and the mean score for radicular pain improved by 50.4% and 72% in the early and late postoperative periods, respectively. The mean VAS score for radicular pain in cases who underwent TLIF and unilateral stabilization due to facetectomy was 8.4 in the preoperative period, 2.1 in the early postoperative period, and 1.4 three months after surgery ( $P < 0.001$ ). There was a significant improvement compared with the preoperative period. In these cases, the mean VAS score for radicular pain improved by 75% and 83.3% in the early and late postoperative periods, respectively.

Leg pain persisted in the early postoperative period in 5 of 13 patients (38.5%) who underwent surgery using the combined approach. However, control radiologic investigations revealed no recurrent or residual disease. Follow-up for these cases included administration of nonsteroidal anti-inflammatory medications and physical therapy and resulted in significant improvement in the leg pain. The radicular pain score in cases who underwent decompression of the intervertebral foramen using facetectomy and removal of the disc material using microdiscectomy showed significant improvement from the early postoperative period compared with cases who were operated on using the combined approach ( $P < 0.01$ ). The correlation analysis

showed a significant relationship between radicular pain and the surgical approach ( $r=0.69$ ,  $P<0.01$ ) (Table 1).

None of the patients experienced any complications, such as dural injury or infections.

#### 4. Discussion

The cases with MFDH were operated on using a combination of translaminar and extraforaminal approaches. Fusion surgery was performed in 7 cases (35%) who underwent facetectomy after the discectomy procedure. The presence of a herniated disc that could not be removed in its single piece or the presence of a multifragmented disc herniation, osteophytes originating from the end plate, and laminotomy large enough to weaken the isthmus support and resulted in facetectomy and perioperative instability. Radicular pain persisted in 38% of the cases, although there was a significant improvement in leg pain in the early postoperative period with the combined use of the translaminar and extraforaminal approaches. However, the cases who underwent facetectomy followed by microdiscectomy, TLIF, and unilateral stabilization noted a significant improvement in leg pain, which started during the early postoperative period. This difference might have been due to significant decompression and removal of the disc space.

The lateral spinal canal, known as the “secret zone,” cannot be accessed using classical surgical methods and is divided into 3 areas, subarticular (lateral recess), foraminal (pedicle), and extraforaminal (far lateral).<sup>[7,10]</sup> Due to anatomic contiguity, a herniated disc in these areas can compress exiting nerve root and dorsal root ganglion superiorly and exiting nerve root at the same level. In addition, foraminal osteophytes can also cause foraminal stenosis and compress the exiting nerve root. The facet joint envelops the intervertebral foramen and lateral aspect of the disc space due to narrowing of the interpedicular space in the cranial direction.<sup>[1,11]</sup> Therefore, access to the “secret zone” during lumbar disc surgery using the translaminar approach requires further facet joint resection at the more cranial levels. In particular, access to the lateral zones using the translaminar approach for MFDH requires more extensive laminotomy. Decompression with facetectomy is recommended, even for isolated far lateral disc herniation, due to the accompanying significant degree of lateral recess stenosis.<sup>[12]</sup> On the other hand, it had been reported that a far lateral approach using endoscopy or microsurgery was sufficient in far lateral disc herniations without lateral reses stenosis.<sup>[1]</sup>

Although various surgical approaches can be employed in extraforaminal and pure foraminal herniated discs, there is no consensus on a standardized approach for treating MFDH.<sup>[10]</sup> Extensive laminotomy increases the risk of weakened or impaired integrity of the pars interarticularis, stress fractures, and instability.<sup>[13]</sup> Ryang et al<sup>[14]</sup> detected late fracture of the pars interarticularis in 2 of 48 cases who were operated on using the combined approach. However, we observed that disc fragments were left inside or outside the foramen because attempts were made to remove multiple degenerated disc fragments by drawing the fragments into the visual field with the aid of a nerve hook and with unilateral control of the neural foramen. For this reason, the combined approach (involving the translaminar and far lateral) is an effective alternative to the unilateral approach in patients with MFDH.<sup>[9,15,16]</sup> Paolini et al<sup>[9]</sup> preferred to use extraforaminal exposure, followed by intraforaminal exposure, in the combined approach. In the present study using the combined approach, the choice of initial approach was determined by the greater disc

volume. As surgical exposure, the combination of translaminar and lateral exposure achieved sufficient decompression in MFDH at the L5-S1 level. However, the combined approach or facetectomy achieved neural decompression at L4–5 or higher levels. MFDH at the L3–4 and L2–3 levels, in particular, required facetectomy and bone removal sufficient to weaken the pars interarticularis to access the discs in the neural foramen from the medial and lateral aspects. Due to segmental instability caused by facetectomy, these cases also underwent unilateral stabilization and interbody fusion, which has been reported as an effective treatment alternative in such cases.<sup>[17,18]</sup> It was noteworthy that these cases exhibited improvement in radicular pain starting in the early postoperative period, whereas cases operated on using the combined approach reported persistence of pain, although there was an improvement in radicular pain. Aoki et al<sup>[19]</sup> reported that unilateral pedicle screw stabilization and TLIF resulted in less improvement in back pain and radicular symptoms in grade 1 and 2 degenerative spondylolisthesis. In our study, unilateral stabilization was performed to prevent iatrogenic instability caused by facetectomy, not for degenerative instability.

Herniated discs in the foraminal and far lateral zones exhibited multifocal localization in 15% and 16.8% of cases in previous studies.<sup>[6,20]</sup> In these cases, the risk of persistent postoperative leg pain or recurrence of pain after a short period of time was reported to be 3 times higher compared with patients with far lateral LDH. More extensive removal of the annulus and facet joint during surgery, postoperative asymmetric disc collapse, and possible segmental instability might have contributed to the higher risk of pain in these cases.<sup>[6]</sup> The persistence of leg pain in the early postoperative period in 5 of 13 cases operated on using the combined approach in this study was associated with extensive manipulation of the dorsal ganglion<sup>[4,6]</sup> and continuous release of inflammatory cells, cytokines, and chemical agents derived from the nucleus pulposus from the annular defect into the area containing the dorsal root ganglion.<sup>[21,22]</sup> The DRG is anatomically located in the intervertebral foramen and the pathologies and the tears formed on the surface of the intervertebral disc that are oriented toward the intervertebral foramen effect the DRG and the nerve root. Omarker and Myers<sup>[23]</sup> have suggested that bioactive substances from the nucleus pulposus may cause pain behavior changes in nerves due to deformation of the nerve by earlier mechanical stimulation. The authors reported that sensitivity to inflammatory substances originating from the nucleus pulposus is increased by joining the DRG to the deformation. After treatment with the combined approach in MFDH cases where the annular tear is close to the dorsal root ganglion, inflammatory mediators from the nucleus pulposus continue to affect the dorsal root ganglion and ultimately it is thought to be caused to continuing radicular pain. It is also thought that the reason why the similar problem is not encountered in each lumbar disc case might be due to the localization of the annular tear and to the relation with the DRG. Pain relief achieved with bed rest and use of nonsteroidal anti-inflammatory medications provides support for this argument. Preservation of the foraminal height by increasing the intervertebral height with TLIF and less extensive manipulation of the dorsal root ganglion while attempting to bring the disc fragment into view are advantages compared with the combined approach. Evacuation of the disc space to perform TLIF also eliminated the source of chemical mediators to which the dorsal ganglia exhibit high sensitivity. Elimination of chemical mediators of pain, in addition to mechanical decompression, contributed to pain relief.

## 5. Conclusion

Although the combined approach is an effective alternative to the classical interlaminar approach in patients with MFDH, sometimes sufficient decompression is unable to obtain. Surgery can be turned into more invasive procedure by facetectomy which leads to iatrogenic instability. In that case, performing TLIF and unilateral segmental stabilization provides sufficient stability and substantial nerve root decompression and pain relief.

### 5.1. Limitations

The most significant limitations of this study were its retrospective design and low number of cases. However, it was clear that early postoperative pain was a reason for dissatisfaction in our cases. The lack of measurement of annular defects in cases who underwent fragmentectomy using the combined approach was another limitation of this study.

## References

- [1] Epstein NE. Foraminal and far lateral lumbar disc herniations: surgical alternatives and outcome measures. *Spinal Cord* 2002;40:491–500.
- [2] Yue JJ, Scott DL, Han X, et al. The surgical treatment of single level multi-focal subarticular and paracentral and/or far-lateral lumbar disc herniations: the single incision full endoscopic approach. *Int J Spine Surg* 2014;8:16.
- [3] Siebner HR, Faulhauer K. Frequency and specific surgical management of far lateral lumbar disc herniations. *Acta Neurochir* 1990;105:124–31.
- [4] Hodges SD, Humphreys SC, Eck JC, et al. The surgical treatment of far lateral L3-L4 and L4-L5 disc herniations. A modified technique and outcomes analysis of 25 patients. *Spine* 1999;24:1243–6.
- [5] Jenis LG, An HS, Gordin R. Foraminal stenosis of the lumbar spine: a review of 65 surgical cases. *Am J Orthop (Belle Mead NJ)* 2001;30:205–11.
- [6] Chang SB, Lee SH, Ahn Y, et al. Risk factor for unsatisfactory outcome after lumbar foraminal and far lateral microdecompression. *Spine* 2006;31:1163–7.
- [7] Macnab I. Negative disc exploration. An analysis of the causes of nerve-root involvement in sixty-eight patients. *J Bone Joint Surg Am* 1971; 53:891–903.
- [8] Marquardt G, Bruder M, Theuss S, et al. Ultra-long-term outcome of surgically treated far-lateral, extraforaminal lumbar disc herniations: a single-center series. *Eur Spine J* 2012;21:660–5.
- [9] Paolini S, Ciappetta P, Raco A, et al. Combined intra-extracanal approach to lumbosacral disc herniations with bi-radicular involvement. Technical considerations from a surgical series of 15 cases. *Eur Spine J* 2006;15:554–8.
- [10] Reinshagen C, Redjal N, Molcanyi M, et al. Surgical approaches to the Lumbar Hidden Zone: current strategies and future directions. *EBioMedicine* 2015;2:1005–7.
- [11] Schlesinger SM, Fankhauser H, de Tribolet N. Microsurgical anatomy and operative technique for extreme lateral lumbar disc herniations. *Acta Neurochirurgica* 1992;118:117–29.
- [12] Epstein NE, Epstein JA, Carras R, et al. Far lateral lumbar disc herniations and associated structural abnormalities. An evaluation in 60 patients of the comparative value of CT, MRI, and myelo-CT in diagnosis and management. *Spine (Phila Pa 1976)* 1990;15:534–9.
- [13] Ivanov AA, Faizan A, Ebrahim NA, et al. The effect of removing the lateral part of the pars interarticularis on stress distribution at the neural arch in lumbar foraminal microdecompression at L3-L4 and L4-L5: anatomic and finite element investigations. *Spine* 2007; 32:2462–6.
- [14] Ryang YM, Rohde I, Ince A, et al. Lateral transmuscular or combined interlaminar/paraisthmic approach to lateral lumbar disc herniation? A comparative clinical series of 48 patients. *J Neurol Neurosurg Psychiatry* 2005;76:971–6.
- [15] Hassler W, Brandner S, Slansky I. Microsurgical management of lateral lumbar disc herniations: combined lateral and interlaminar approach. *Acta Neurochir* 1996;138:907–10.
- [16] Hejazi N, Witzmann A, Hergan K, et al. Combined transarticular lateral and medial approach with partial facetectomy for lumbar foraminal stenosis. Technical note. *J Neurosurg* 2002;96(1 suppl):118–21.
- [17] Fernandez-Fairen M, Sala P, Ramirez H, et al. A prospective randomized study of unilateral versus bilateral instrumented posterolateral lumbar fusion in degenerative spondylolisthesis. *Spine* 2007;32:395–401.
- [18] Kabins MB, Weinstein JN, Spratt KF, et al. Isolated L4-L5 fusions using the variable screw placement system: unilateral versus bilateral. *J Spinal Disord* 1992;5:39–49.
- [19] Aoki Y, Yamagata M, Ikeda Y, et al. A prospective randomized controlled study comparing transforaminal lumbar interbody fusion techniques for degenerative spondylolisthesis: unilateral pedicle screw and 1 cage versus bilateral pedicle screws and 2 cages. *J Neurosurg Spine* 2012;17:153–9.
- [20] Abdullah AF, Wolber PG, Warfield JR, et al. Surgical management of extreme lateral lumbar disc herniations: review of 138 cases. *Neurosurgery* 1988;22:648–53.
- [21] Habtemariam A, Gronblad M, Virri J, et al. A comparative immunohistochemical study of inflammatory cells in acute-stage and chronic-stage disc herniations. *Spine* 1998;23:2159–65.
- [22] Olmarker K, Blomquist J, Stromberg J, et al. Inflammatory properties of nucleus pulposus. *Spine* 1995;20:665–9.
- [23] Olmarker K, Myers RR. Pathogenesis of sciatic pain: role of herniated nucleus pulposus and deformation of spinal nerve root and dorsal root ganglion. *Pain* 1998;78:99–105.