

# Anesthetic Management with Total Intravenous Anesthesia in Hereditary Spherocytosis

## Herediter Sferositoz'da Total İntravenöz Anestezi ile Anestezi Yönetimi

Betül Kocamer Şimşek<sup>1</sup> , Yunus Baydilek<sup>1</sup>, Ahmet Ziya Şahin<sup>2</sup>, Hakan Darıcı<sup>3</sup>

<sup>1</sup>Department of Anesthesiology and Reanimation, Sanko University School of Medicine, Gaziantep, Turkey

<sup>2</sup>Department of Internal Medicine, Adana Aşkın Tüfekçi Public Hospital, Adana, Turkey

<sup>3</sup>Sanko University School of Medicine, Department of Histology and Embryology, Gaziantep, Turkey

### ABSTRACT

Hereditary spherocytosis (HS) is a type of hemolytic anemia. Anesthetic management of any surgery with HS requires close monitoring of hypothermia, hypoxia, acidosis, and postoperative pain.

We report a case of a 14-year-old male patient with HS scheduled for laparoscopic cholecystectomy. He was operated for splenectomy 5 years prior to admission. Hemoglobin (Hb) was 11.5 g/dL, platelets were 2,97,000 /mL, and total bilirubin was 4.50 mg/dL with direct bilirubin being 0.41 mg/dl. In peripheral blood smear (PBS) before surgery, spherocytosis percentage was 19%. He was premedicated with midazolam. After induction with propofol, fentanyl, and atracurium, anesthesia was maintained with air and O<sub>2</sub> and total intravenous anesthesia (TIVA) was maintained with propofol and remifentanyl. Electrocardiography, non-invasive blood pressure, peripheral oxygen saturation, and end-tidal carbon dioxide were monitored. We used an air warmer blanket to avoid hypothermia. Intraoperative arterial blood gas (ABG) values were evaluated at pH 7.37 (PCO<sub>2</sub> = 38.1 mm Hg, PO<sub>2</sub> = 177 mm Hg, Hb = 11.5 g/dL, and glucose = 109 mg/dL). Furthermore, intraoperative PBS was repeated, and spherocyte percentage was 11%. In post-anesthesia care unit, ABG values at pH 7.36 for PCO<sub>2</sub>, PO<sub>2</sub>, and Hb were 37.4 mm Hg, 210 mm Hg, and 11.4 g/dL, respectively. PBS was repeated on the next day, and spherocyte percentage was 16%. Multimodal analgesia was provided with tramadol, paracetamol, and local infiltration of the surgical site. Paracetamol infusion was given postoperatively three times a day for pain control.

Intraoperative spherocyte percentage was less than that observed in preoperative PBS (11% and 19%, respectively). We consider that TIVA decreased spherocytes owing to appropriate anesthetic management, ABG stabilization, and normothermia each, either alone or together. On the next day, the spherocyte percentage was increased (16%) but still remained below the first spherocyte count. We consider that this is due to good pain control and well-balanced hydration. In conclusion, TIVA provided a safe anesthetic management.

**Keywords:** Hereditary spherocytosis, anesthesia management, TIVA, propofol

### ÖZ

Herediter sferositoz (HS) bir hemolitik anemi türüdür. HS hastasında her tür cerrahide anestezi yönetiminde hipotermi, hipoksi, asidoz ve postoperatif ağrı açısından yakından izlenmelidir.

Beş yıl önce splenektomi operasyonu olan laparoskopik kolesistektomi planlanan 14 yaşındaki erkek HS hasta olgusunu sunduk. Ameliyattan önce hemoglobin (Hb) 11,5g/dL, total bilirubin 4,50 mg/dL direkt bilirubin 0,41mg/dL, trombositler 297K/mL, periferik kan yaymasında (PKY) sferositoz yüzdesi %19 idi. Midazolam ile premedikasyon yapıldı. Propofol, fentanil ve atrakuryum ile anestezi induksiyon sağlandı, propofol ve remifentanil ile Total İntravenöz Anestezi (TIVA) ve hava, O<sub>2</sub> ile idame sağlandı. Nabız, tansiyon arteryel, oksijen saturasyonu, end-tidal karbondioksit (EtCO<sub>2</sub>) izlendi. Üflemleri ve alt gövde battanisiyesi ile hasta ısıtıldı. Ameliyatta arteryel kan gazı (AKG) değerleri PH 7,37, PCO<sub>2</sub> 38,1 mmHg, PO<sub>2</sub> 177 mmHg, Hb 11,5 g/dL glukoz 109 mg/dL olarak değerlendirildi. Ayrıca ameliyat sırasında PKY tekrarlandı ve sferosit yüzdesi %11 olarak belirlendi. Postoperatif AKG'da pH 7,36, PCO<sub>2</sub> 37,4 mmHg, PO<sub>2</sub> 210 mmHg, Hb 11,4 g/dL olarak belirlendi. PKY ertesi gün tekrarlandı ve sferosit yüzdesi % 16 olarak belirlendi. Multimodal analjezi tramadol, parasetamol ve insizyon yerlerine lokal anestezi infiltrasyonu ile sağlandı. Ameliyat sonrası ağrı kontrolü günde üç kez parasetamol infüzyon ile sağlandı.

Operasyon sırasında sferositoz yüzdesi önceki PKY oranla (%11 /%19) daha düşük bulundu. TIVA'nın tek başına veya birlikte iyi anestezi yönetimi, iyi AKG stabilizasyonu, normotermi sağladığı için sferosit sayısında azalma sağladığını düşünüyoruz. Ertesi gün artış görülmüş (%16) ancak yine de ilk PKY değerinin altında kalmıştır. Biz bunu iyi ağrı kontrolü ve iyi dengelenmiş hidrasyon nedeniyle olduğunu düşünmekteyiz. Sonuç olarak, TIVA güvenli bir anestezi yönetimini sağlamıştır.

**Anahtar kelimeler:** Herediter sferositoz, total intravenöz anestezi, propofol, anestezi yönetimi

This study was presented in Sanko University Innovation in Medicine Summit-2, 5-7 May 2016, Gaziantep, Turkey.

**ORCID IDs of the authors:** B.K.Ş. 0000-0001-8220-9542

**Corresponding Author/Sorumlu Yazar:** Betül Kocamer Şimşek E-mail/E-posta: btlkcmr@gmail.com

**Received/Geliş Tarihi:** 05.10.2017 • **Accepted/Kabul Tarihi:** 11.10.2017

©Copyright by 2018 Gaziantep University School of Medicine - Available online at www.eurjther.com

©Telif Hakkı 2018 Gaziantep Üniversitesi Tıp Fakültesi - Makale metnine www.eurjther.com web sayfasından ulaşılabilir

## INTRODUCTION

Hereditary spherocytosis (HS) is an inherited hemolytic disorder with clinical features ranging from an asymptomatic condition to a fulminant hemolytic anemia requiring erythrocyte transfusion; incidence of HS is 1:5000. The primary lesion is reduced deformability of erythrocytes due to defects in the membrane protein ankyrin, spectrin, or protein 4.2 (1). The patient was admitted for laparoscopic cholecystectomy under general anesthesia with total intravenous anesthesia (TIVA). Hypothermia, hypoxia, and acidosis were considered and monitored with arterial blood gas (ABG) values, and an air warmer blanket was used to avoid hypothermia. In addition, TIVA was chosen for a good recovery to avoid hypoxia during the extubation period.

## CASE PRESENTATION

We report a case of a 14-year-old male patient (weight, 39.9 kg; height, 161 cm) with HS scheduled for laparoscopic cholecystectomy after his parents provided written consent. Another approval was obtained from his parents for the case presentation. He presented with repeated episodes of jaundice, loss of appetite, easy fatigability, and pain in the right hypochondria. Hemoglobin (Hb) was 11.5 g/dL, and vitamin B12 level was 114 pg/ml. Ultrasonography of the abdomen showed no spleen and echogenic sludge in the gallbladder. He was operated for splenectomy 5 years ago. Platelets (2,97,000 /mL), prothrombin time (16.1 s), INR (1.30), total bilirubin (4.50 mg/dL) with direct bilirubin (0.41 mg/dL), and liver enzymes were normal. Other routine investigations were unremarkable. Peripheral blood smear (PBS) was performed in another institution, and spherocytosis percentage was 19% 4 days before the surgery. Reticulocyte percentage was 2.5%.

In the operation theater, two wide-bore cannulae were secured. The patient was premedicated with midazolam 1 mg (Dalizom; Generica, İstanbul, Türkiye). After induction with propofol (2 mg/kg; Propofol; Fresenius Kabi, Graz, Austria) and fentanyl (1 µg/kg; Talinat; Vem ilaç, Ankara, Türkiye) and intubation facilitated by atracurium (Tracrium; GSK, S.p.A, Italia), anesthesia was maintained with air and O<sub>2</sub> and TIVA with propofol and remifentanyl (Ultiva; GSK, S.p.A, Italia).

Intraoperative care was ensured to avoid hypoxia, hypothermia, and acidosis. Electrocardiography, non-invasive blood pressure, peripheral oxygen saturation, end-tidal carbon dioxide, and esophageal temperature probe were monitored throughout the surgery. Temperature was maintained between 36.3°C and 36.7°C.

Intraoperative ABG values evaluated at pH 7.37 for PCO<sub>2</sub>, PO<sub>2</sub>, Hb, glucose, and HCO<sub>3</sub> were 38.1 mm Hg, 177 mm, 11.5 g/dL, 109 mg/dl, and 22.0 mmol/l, respectively. In addition, intraoperative PBS was repeated, and spherocyte percentage was found to be 11% (Figure 1). In post-anesthesia care unit (PACU), ABG values evaluated at pH 7.36 for PCO<sub>2</sub>, PO<sub>2</sub>, Hb, and HCO<sub>3</sub> were 37.4 mm Hg, 210 mm Hg, 11.4 g/dL, and 21.6 mmol/L, respectively. PBS was repeated on the next day, and spherocyte percentage was 16% (Figure 2).

Surgery continued for 45 min and was uneventful. Multimodal analgesia was provided using tramadol, paracetamol, and local infiltration of the surgical site with bupivacaine 0.25% and lidocaine 2% mixture. Patient was extubated after surgery, had a good recovery, and was shifted to PACU for observation. Postoperatively, 1 mg/kg paracetamol infusion was given three times a day for pain control. There was no need for pain medicine. He was discharged on the third day.

## DISCUSSION

Patients with HS typically present with anemia, jaundice, gallstones, and splenomegaly. There may be a similar family history. Many patients have compensated hemolysis and a normal Hb level with reticulocytosis. Complications of HS include cholelithiasis, a consequence of chronic hemolysis; aplastic crisis, most commonly after parvovirus B19 infection; hemolytic crisis during intercurrent infection; and megaloblastic crisis in the presence of folic acid deficiency (1). Acute chest syndrome, onset of new lobar infiltration on chest X-ray (excluding atelectasis) associated with fever, respiratory distress, or chest pain has been reported (2).

If gallstones are present, cholecystectomy may be performed simultaneously with splenectomy or at a later date (3). In our case,

Figure 1. Intraoperative peripheral blood smear

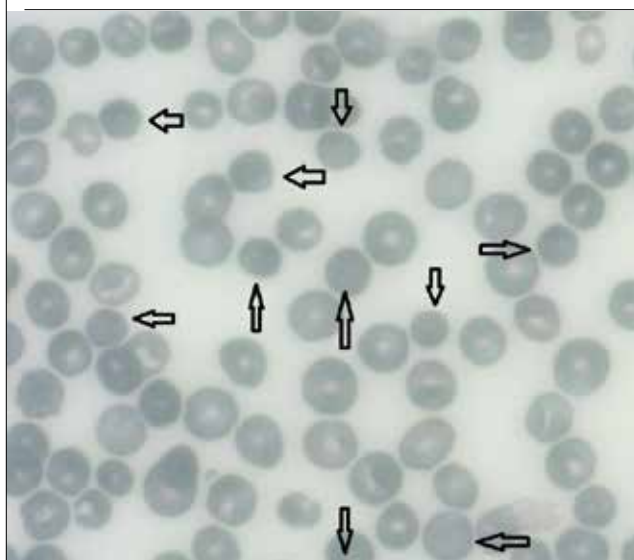
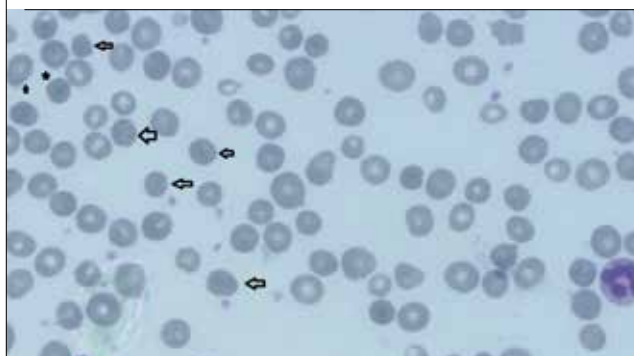


Figure 2. Postoperative peripheral blood smear



cholecystectomy operation was preferred later. Anesthetic management of HS involves hydration and avoidance of hypoxia, hypothermia, and acidosis and a good pain management.

Intraoperatively, avoidance of hypoxemia is the key. Sedatives and opioid analgesics should be used with extreme caution to prevent respiratory depression, hypoxia, and sickling. Blood loss should be replaced whenever necessary. Normothermia should be maintained to minimize vasoconstriction and associated circulatory stasis (4).

In our case, ABG values and temperature were normal. Furthermore, spherocyte percentage was 11% in intraoperative PBS less than preoperative smear percentage (19%). Recovery was well enough after surgery. We consider that TIVA with propofol and remifentanyl did not increase spherocyte percentage. This could be due to appropriate anesthetic management, normothermia, and appropriate ABG stabilization each, either alone or together.

However, on the next day, spherocyte percentage increased (16%) but still remained below the first spherocyte value. We consider that this is because of good pain control and well-balanced hydration.

## CONCLUSION

Perioperative management of HS largely depends on the severity of anemia and the degree of hemolysis. Anesthetic goals include avoidance of hypoxia, acidosis, and hypothermia and good pain management postoperatively. Patients with HS are at an increased risk of developing perioperative complications, such as aplastic crisis and hemolytic episodes, for which awareness and vigilance are important. TIVA with propofol and remifentanyl decreased spherocytosis percentage and provided an appropriate anesthetic management. We concluded that TIVA is safe for patients with HS.

**Informed Consent:** Written informed consent was obtained from the parents of the patient who participated in this study.

**Peer-review:** Externally peer-reviewed.

**Author Contributions:** Concept – B.Ş.; Design - B.Ş.; Supervision – A.Z.Ş.; Resource - B.Ş.; Materials – Y.B.; Data Collection and/or Processing - H.D.; Analysis and/or Interpretation - B.Ş.; Literature Search - B.Ş.; Writing - B.Ş.

**Conflict of Interest:** No conflict of interest was declared by the authors.

**Financial Disclosure:** The authors declared that this study has received no financial support.

**Hasta Onamı:** Yazılı hasta onamı bu çalışmaya katılan hastanın ailesinden alınmıştır.

**Hakem Değerlendirmesi:** Dış Bağımsız.

**Yazar Katkıları:** Fikir - B.Ş.; Tasarım - B.Ş.; Denetleme - A.Z.Ş.; Kaynaklar - B.Ş.; Malzemeler - Y.B.; Veri Toplanması ve/veya İşlemesi – H.D.; Analiz ve/veya Yorum - B.Ş.; Literatür Taraması - B.Ş.; Yazıyı Yazan - B.Ş.

**Çıkar Çatışması:** Yazarlar çıkar çatışması bildirmemişlerdir.

**Finansal Destek:** Yazarlar bu çalışma için finansal destek almadıklarını beyan etmişlerdir.

## REFERENCES

1. Bolton-Maggs PH, Langer JC, Iolascon A, Tittensor P, King MJ; General Haematology Task Force of the British Committee for Standards in Haematology. Guidelines for the diagnosis and management of hereditary spherocytosis-2011 update. *Br J Haematol* 2012; 6: 156: 37-49. [\[CrossRef\]](#)
2. Hassan A, Babadoko AA, Isa AH, Abunimye P. Hereditary Spherocytosis in a 27-year old female: casereport. *Annals of African Medicine* 2009; 8: 61-3. [\[CrossRef\]](#)
3. Nobili C, Romano F, Ciravegna AL, Garancini M, Degrate L, Uggeri F, et al. Consecutive concomitant laparoscopic splenectomy and cholecystectomy: an Italian experience of 30 patients and proposition of a technique. *J Laparoendosc Adv Surg Tech* 2011; 21: 313-7 [\[CrossRef\]](#)
4. Malliwal A, Mehta S, Bakhshi R, Mahapatra B. Anaesthetic considerations for patient of Hereditary Spherocytosis for splenectomy and cholecystectomy: A case report. *Indian Journal of Basic and Applied Medical Research* 2014; 11: 295-7.

### How to cite:

Şimşek Kocamer B, Baydilek Y, Şahin AZ, Darıcı H. Anesthetic Management with Total Intravenous Anesthesia in Hereditary Spherocytosis. *Eur J Ther* 2018; 24: 64–6.