

# Triple Innominate Osteotomy for Early Closure of the Triradiate Cartilage after Hip Joint Injury: A Pediatric Case Report

Gökhan Bülent Sever<sup>1</sup> , Mehmet Cenk Cankuş<sup>1</sup> , Aydın Büdeyri<sup>1</sup> ,  
Mehmet Dokur<sup>2</sup> 

<sup>1</sup>Department of Orthopaedics, Sanko University School of Medicine, Gaziantep, Turkey

<sup>2</sup>Department of Emergency Medicine, Biruni University School of Medicine, İstanbul, Turkey

## ABSTRACT

Acetabular fractures are less common in children than those in adults. Even these fractures are rarely seen in infants and usually such fractures require high-impact trauma. Orthopedic surgeons often recommend conservative treatment for acetabular fractures to accommodate remodeling features. In addition, pelvic osteotomies have demonstrated good results; specifically, triple innominate osteotomy treatment has been proven effective. In this study, we report the case of an 8 year-old girl who suffered from hobbling because of preclosure of triradiate cartilage and hip subluxation with left femoral diaphysis fracture resulting in malunion and lower extremity shortening. First we applied osteotomy and plate and screw osteosynthesis for femoral malunion and afterwards triple innominate osteotomy for subluxation caused by acetabular traumatic dysplasia and preclosure of triradiate cartilage. The results were quite satisfying in this case.

**Keywords:** Acetabular dysplasia, children, early closure, triple innominate osteotomy, triradiate cartilage injury

## INTRODUCTION

Acetabulum fractures in infants are rare, with occurrences estimated at one in a thousand (1). Infant fractures are different from adult fractures. A high-impact trauma is necessary for displaced fractures, and particularly for acetabulum fractures, because of the presence of large amounts of cartilage tissue, thick periosteum, joint elasticity, and ligament force. In infants, pelvic and acetabulum fractures unite easily, with a high percentage of remodeling; thus, physicians generally choose conservative treatment (2-4). Triradiate Cartilage (TRC) is the most important feature of acetabulum fractures in infants, and this feature may be affected during treatment. Furthermore, the acetabulum may stop growing, which can lead to acetabular dysplasia and hip dislocation (5, 6). This study suggested that post-traumatic TRC injuries may be unilateral or bilateral, and that ipsilateral/contralateral joint dislocation and femoral fractures occur when TRC is injured (7-11). When acetabular dysplasia develops, physicians generally choose periacetabular and Chiari osteotomies as the usual surgical treatment.

The aim of this study is to emphasize that examinations of lower extremity injuries resulting from high-impact pediatric trauma should also include a check for pelvic ring injuries, regardless of the rarity with which such injuries occur. Undetected TRC injury may lead to iliac dysplasia. This study emphasizes that triple os-

teotomy is a good choice for treating post-traumatic acetabular dysplasia and hip subluxation.

## CASE PRESENTATION

An 8-year-old girl came to us with a hobbling problem. Her case history indicated a traffic accident when she was one-and-a-half years old, resulting in a left femoral fracture. After the traffic accident, she was treated with a pelvipedal hip spica cast. This problem in the left lower extremity of the patient gradually increased within 6 months after the accident. In this process, her parents had not applied for treatment of this patient in any health care institution.

The physical examination revealed a positive Trendelenburg's sign, and both hip joints' movement capacity was full with her left lower extremity. Spina Iliaca Anterior Superior-medial malleol distance measurements indicated that her left lower extremity was 2.5 cm shorter than her right extremity. Plain radiographies (X Ray Machine; Siemens, Erlangen, Germany) indicated left acetabular dysplasia, left hip subluxation, and left femur rotational and angular malunion (Figures 1a, b). In addition, a computed tomography (CT) scan (Somatom X; Siemens, Erlangen, Germany) of her hips indicated that left TRC had preclosed on all 3 legs of TRC (Figure 1c).

**ORCID IDs of the authors:** G.B.S. 0000-0002-3096-5968; M.C.C. 0000-0003-4469-3358; A.B. 0000-0003-1894-5435; M.D. 0000-0003-2119-3801.

**Corresponding Author:** Gökhan Bülent Sever **E-mail:** gokhansever@hotmail.com

**Received:** 03.10.2017 • **Accepted:** 31.01.2018

Figure 1. a-c. Preoperative plain radiographic images and pelvic CT scan. (a) preoperative left femur and pelvis AP radiography. (b) preoperative left femur lateral radiography. (c) preoperative left innominate cartilage arrest showing pelvic CT scan

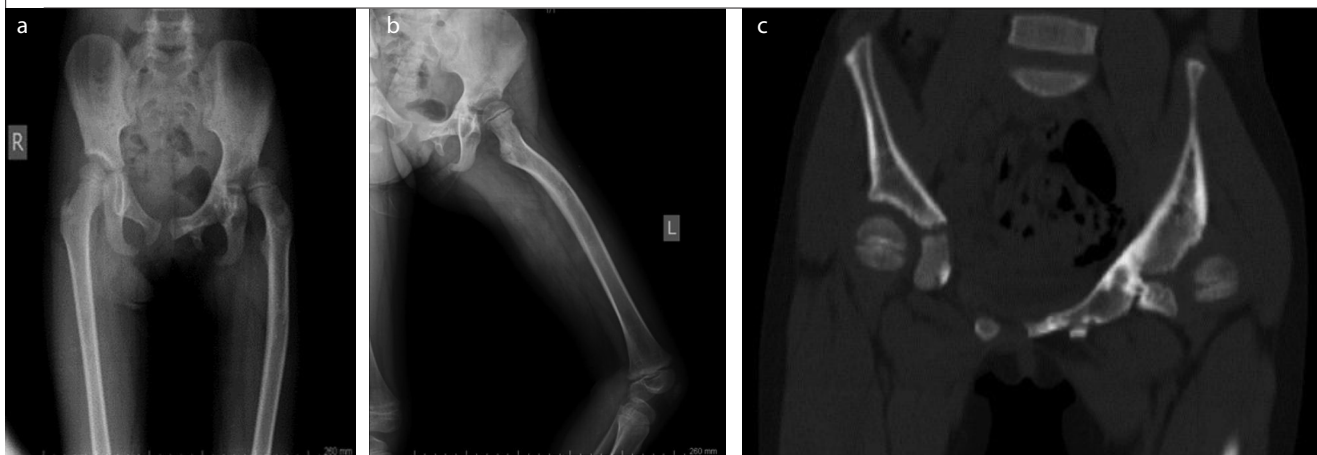
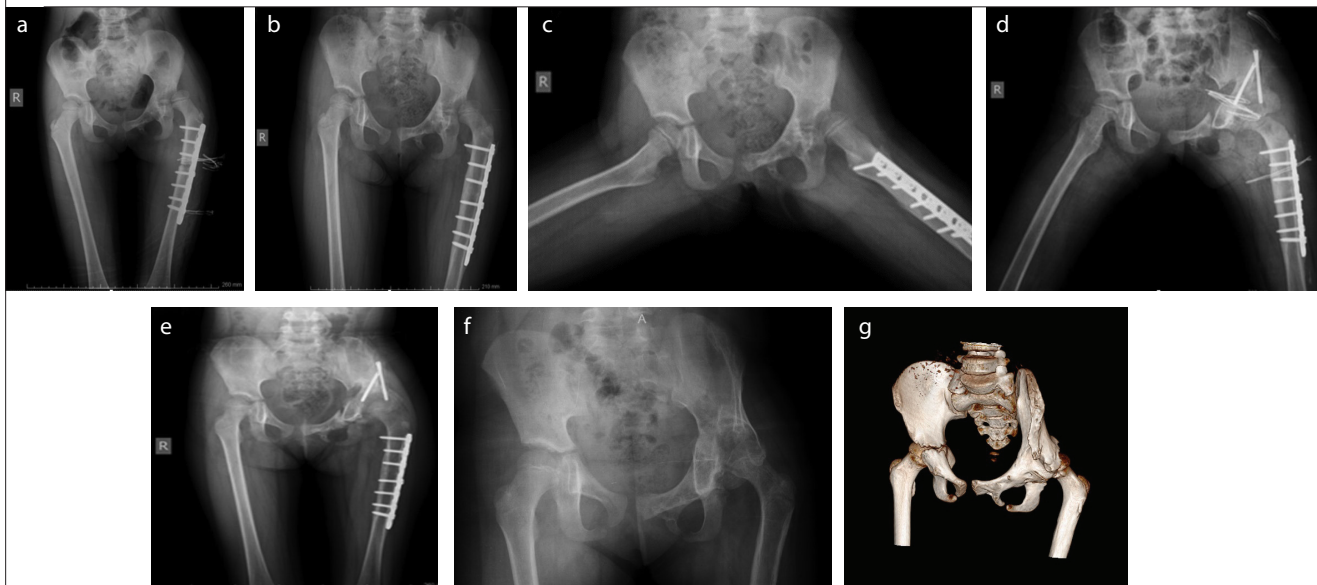


Figure 2. a-g. Postoperative plain radiographic images. (a) AP radiography of the left femur after correction of malunion (postoperative 1<sup>st</sup> day). (b) AP radiography of the left femur after correction of malunion (postoperative 6<sup>th</sup> month). (c) Lateral radiography of the left femur after correction of malunion (postoperative 6<sup>th</sup> month). (d) AP radiography of the left femur and pelvis after acetabular osteotomy (postoperative 1<sup>st</sup> day). (e) AP radiography of the left femur and pelvis after acetabular osteotomy (postoperative 3<sup>rd</sup> month). (f) AP radiography of the left femur and pelvis after acetabular osteotomy (postoperative 2<sup>nd</sup> year). (g) Three-dimensional pelvic computed tomography scan. (postoperative 2<sup>nd</sup> year)



As a first surgical step, we applied malunion osteotomy and plate and screw using an osteosynthesis technique for femoral problems using lateralization, Dynamic compression plate (DCP) and screw (Locking LC DCP Narrow Plate and 3.5 mm screw; Zimed, Gaziantep, Turkey) (Figures 2a-c). At 6 months postoperatively, we applied a triple innominate osteotomy to the acetabulum, thus achieving coverage of the femoral head (Figure 2d, e). The, postoperatively, (CE angle calculation was 12.6°. This operation utilized an ilioinguinal and posterior ischion incision technique. The patient exhibited decreased hobbling and stable CE angles as compared to initial postoperative calculations approximately 2-year postoperatively (Figures 2f, g).

These studies have been performed in accordance with the ethical standards laid down in the Declaration of Helsinki. For this purpose written patient consent form was obtained from the patient’s parents to use this patient’s information for a scientific study.

**DISCUSSION**

Research has determined that femoral fractures with same-sided triradiate injuries are rare (7). Infants are treated with bed rest, pelvic orthoses, skeleton traction, or a cast for pelvic fractures (4). Physicians choose conservative treatment because of its successful union and remodeling rates (3, 12). However, some studies

indicate that conservative treatment of displaced unstable pelvic fractures result in long-term morbidity and functional problems (6). McDonald (13) used conservative treatment on 15 infants diagnosed with unstable pelvic fractures and reported an increase in long-term morbidity, including delayed union, sacro-iliac fusion, and extremity length differences. Schwarz et al. (12) investigated anatomic reduction of pelvic ring fractures, indicating that conservative treatment may cause pelvic asymmetry. Our patient received conservative treatment for femoral and triradiate injuries; however, remodeling of the femur was insufficient and the acetabulum had ceased development as a result of acetabular dysplasia and iliac subluxation.

Bucholz suggests two simple patterns for triradiate trauma: a split-type as seen in Salter-Harris type-1/2 injuries; and crush-injury type as seen in type-5 traumas, which is hard to detect in X-ray imaging (14). We could not apply the Salter-Harris classification in this case because we could not get the first X-rays of the patient taken after the accident.

Furthermore, when we have consulted this patient, acetabular dysplasia and femoral head subluxation was already developed.

The patient's age is important for sequela formations in trauma. According to Bucholz, serious deformities have not been reported in traumas older than 11 years (14). In addition, according to Gebstein, when triradiate fusion is occurring acetabular dysplasia and hip dislocation with dysplasia occurs at half the normal rate and also, iliopubic fusion has a minimal effect on acetabular development (15). In our patient, all tree parts of TRC had closed prematurely, and the hip had also subluxated. Current literature suggested that almost half of the cases with TRC injuries cannot be diagnosed based on an analysis of radiography reports (8). As a result, patients diagnosed with femoral fractures should undergo examination of TRC and we recommend tomographic evaluations in suspicious cases to prevent further complications.

In cases exhibiting completely arrested development of TRC, studies have indicated good results following epiphysiodesis. Badina et al. (7) established that in all successful cases, epiphysiodesis had been applied before the development of femoral head subluxation. However, in our case, patient follow-up was poor, and clinical examination indicated hip subluxation. Thus, epiphysiodesis treatment was not considered. Trousdale and Ganz (5) indicated successful results with pelvic osteotomies in cases with a decreased coverage of the femoral head due to post-traumatic acetabular dysplasia and applied periacetabular osteotomy in two of the five cases exhibiting post-traumatic acetabular dysplasia, with good results. Scuderi and Bronson (9) applied a Chiari Osteotomy to one of the two cases with post-traumatic dysplasia with good results. The literature revealed no documentation concerning the application of acetabular triple innominate osteotomy to increase the femoral head coverage.

In our 8-year-old patient, triple innominate osteotomy increased the femoral coverage and balanced the CE angle to normal limits. After 2 year, the measurement was still 12.6°. In this study calculating the preoperative CE angle was not possible because of a subluxated hip. Hence, in our case CE angle measured post-

operatively confirmed that triple innominate osteotomy may be the correct treatment.

## CONCLUSION

We can state that triple osteotomy may also be considered as a treatment option in post-traumatic dysplasia cases when the femoral head covering is insufficient after our short time followed case experience. Furthermore, for patients exhibiting both hip dysplasia and malunion at the lower extremities, malunion should be treated prior to dysplasia. In addition, acetabular fractures of children can be missed in emergency services. For this reason, emergency physicians should be careful about its early diagnosis and complications.

**Informed Consent:** Written informed consent was obtained from the parents of the patient who participated in this case.

**Peer-review:** Externally peer-reviewed.

**Author Contributions:** Concept - G.B.S., M.C.C., A.B.; Design - G.B.S., M.C.C., A.B.; Supervision - G.B.S., A.B.; Resources - G.B.S., M.C.C., A.B.; Materials - M.D., A.B.; Data Collection and/or Processing - M.D., G.B.S., M.C.C.; Analysis and/or Interpretation - G.B.S., M.C.C., M.D.; Literature Search - G.B.S., M.C.C., A.B., M.D.; Writing Manuscript - G.B.S., M.D.; Critical Review - M.C.C., A.B., M.D.

**Conflict of Interest:** The authors have no conflicts of interest to declare.

**Financial Disclosure:** The authors declared that this study has received no financial support.

## REFERENCES

1. Karunakar MA, Goulet JA, Mueller KL, Bedi A, Le TT. Operative treatment of unstable pediatric pelvis and acetabular fractures. *J Pediatr Orthop* 2005; 25: 34-8.
2. Lee DH, Jeong WK, Inna P, Noh W, Lee DK, Lee SH. Bilateral sacroiliac joint dislocation (anterior and posterior) with triradiate cartilage injury: a case report. *J Orthop Trauma* 2011; 25: e111-4.
3. Musemeche CA, Fischer RP, Cotler HB, Andrassy RJ. Selective management of pediatric pelvic fractures: a conservative approach. *J Pediatr Surg* 1987; 22: 538-40.
4. Trousdale RT. Acetabular osteotomy: indications and results. *Clin Orthop Relat Res* 2004; 182-7.
5. Trousdale RT, Ganz R. Posttraumatic acetabular dysplasia. *Clin Orthop Relat Res* 1994; 124-32.
6. Watts HG. Fractures of the pelvis in children. *Orthop Clin North Am* 1976; 7: 615-24.
7. Badina A, Vialle R, Fitoussi F, Damsin JP. Case Reports: Treatment of Traumatic Triradiate Cartilage Epiphysiodesis. What is the Role of Bridge Resection? *Clin Orthop Relat Res* 2013; 471: 3701-5.
8. Heeg M, Visser JD, Oostvogel HJ. Injuries of the acetabular triradiate cartilage and sacroiliac joint. *J Bone Joint Surg Br* 1988;70: 34-7.
9. Scuderi G, Bronson MJ. Triradiate cartilage injury: report of two cases and review of the literature. *Clin Orthop Relat Res* 1987; 179-89.
10. Sener M, Karapinar H, Kazimoglu C, Yagdi S, Akgun U. Fracture dislocation of sacroiliac joint associated with triradiate cartilage injury in a child: a case report. *J Pediatr Orthop B* 2008; 17: 65-8.
11. Stäbe-Heyl J, Slongo T, Beck M, Ganz R. Bilateral post-traumatic acetabular dysplasia. *Orthopade* 2006; 35: 566-70.
12. Schwarz N, Posch E, Mayr J, Fischmeister FM, Schwarz AF, Ohner T. Long-term results of unstable pelvic ring fractures in children. *Injury* 1998; 29: 431-3.
13. McDonald GA. Pelvic disruptions in children. *Clin Orthop Relat Res* 1980; 130-4.

14. Bucholz RW, Ezaki M, Ogden JA. Injury to the acetabular triradiate physeal cartilage. *J Bone Joint Surg Am* 1982; 64: 600-9.
15. Gepstein R, Weiss RE, Hallel T. Acetabular dysplasia and hip dislocation after selective premature fixation of the triradiate cartilage: an experimental study in rabbits. *J Bone Joint Surg Br* 1984; 66: 334-6.

**How to cite:**

Sever GB, Cankuş MC, Büdeyri A, Dokur M. Triple Innominate Osteotomy for Early Closure of the Triradiate Cartilage after Hip Joint Injury: A Pediatric Case Report. *Eur J Ther* 2019; 25(1): 82–5.